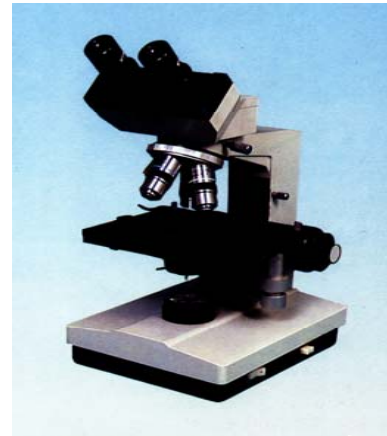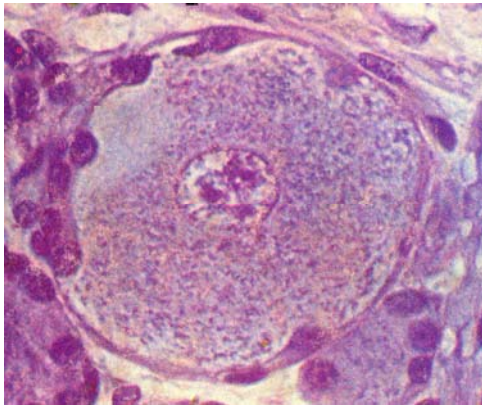



Histology and Embryology



Chapter 1 Introduction and Cell	Chapter 11 Digestive Tract
Chapter 2 Epithelial tissue	Chapter 12 Digestive Gland
Chapter 3 Connective Tissue	Chapter 13 Respiratory System
Chapter 4 Blood	Chapter 14 Urinary System
Chapter 5 Cartilage and Bone	Chapter 15 Endocrine System
Chapter 6 Muscle Tissue	Chapter 16 Sense Organ
<u>Chapter 7 Nerve Tissue</u>	Chapter 17 Male Reproduction
Chapter 8 Circulatory System	Chapter 18 Female Reproduction
Chapter 9 Immune System	Chapter 19 Embryology 1
Chapter 10 Skin	Chapter 20

Chapter 7 Nerve Tissue

I Slides

II Sections

NO.13 spinal cord

NO.20 sciatic nerve

NO.21 sciatic nerve

NO.22 tactile corpuscle

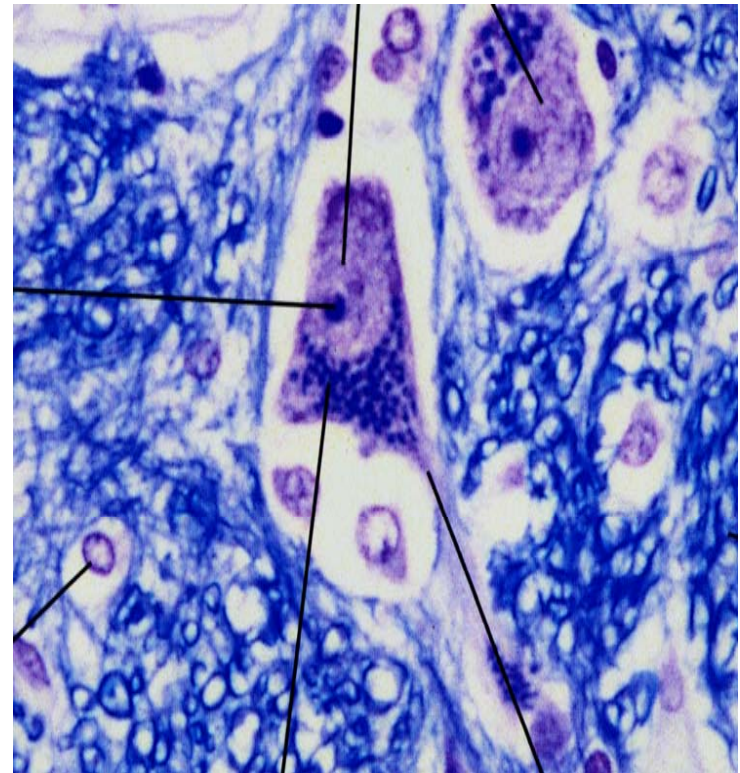
NO.45 lamellar corpuscle

NO.23 motor end plate

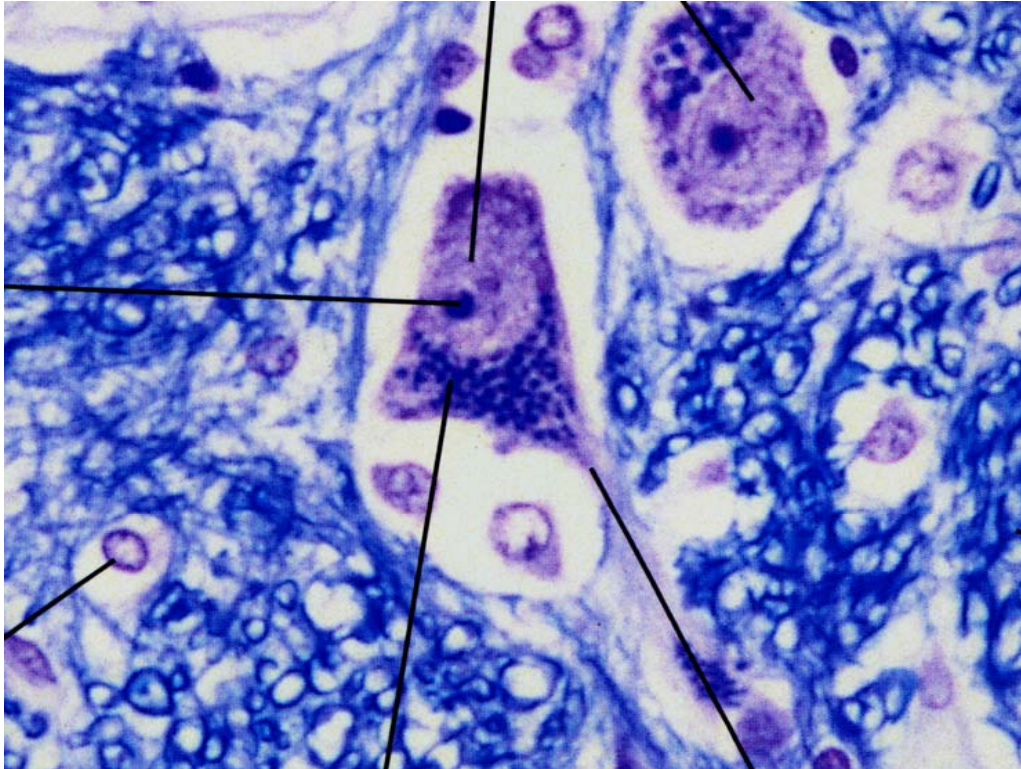
III Drawing:neron

IV EM photos: 26-31

V Summary



III Drawing:neuron



Material :

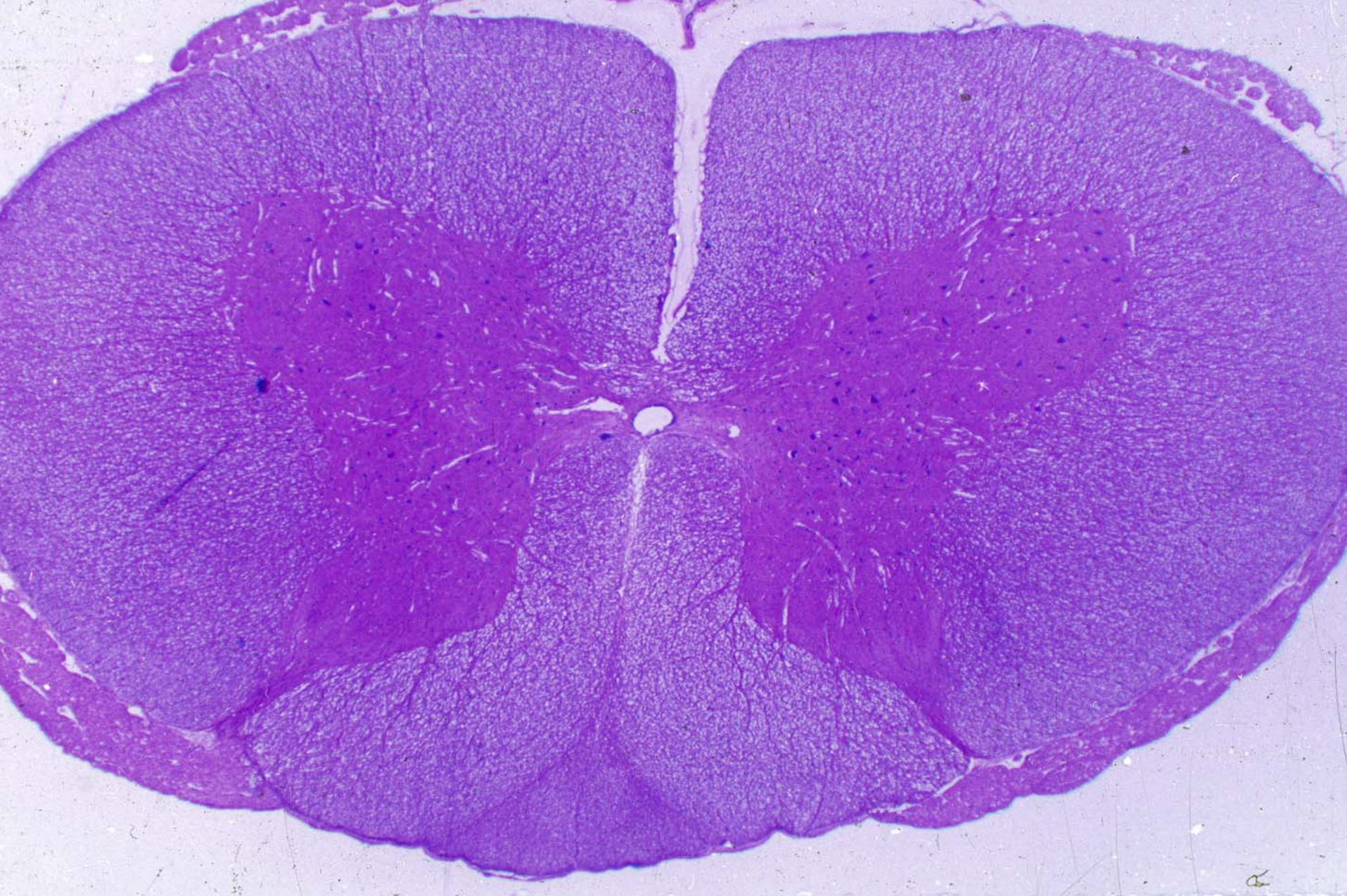Staining :

Amplification :

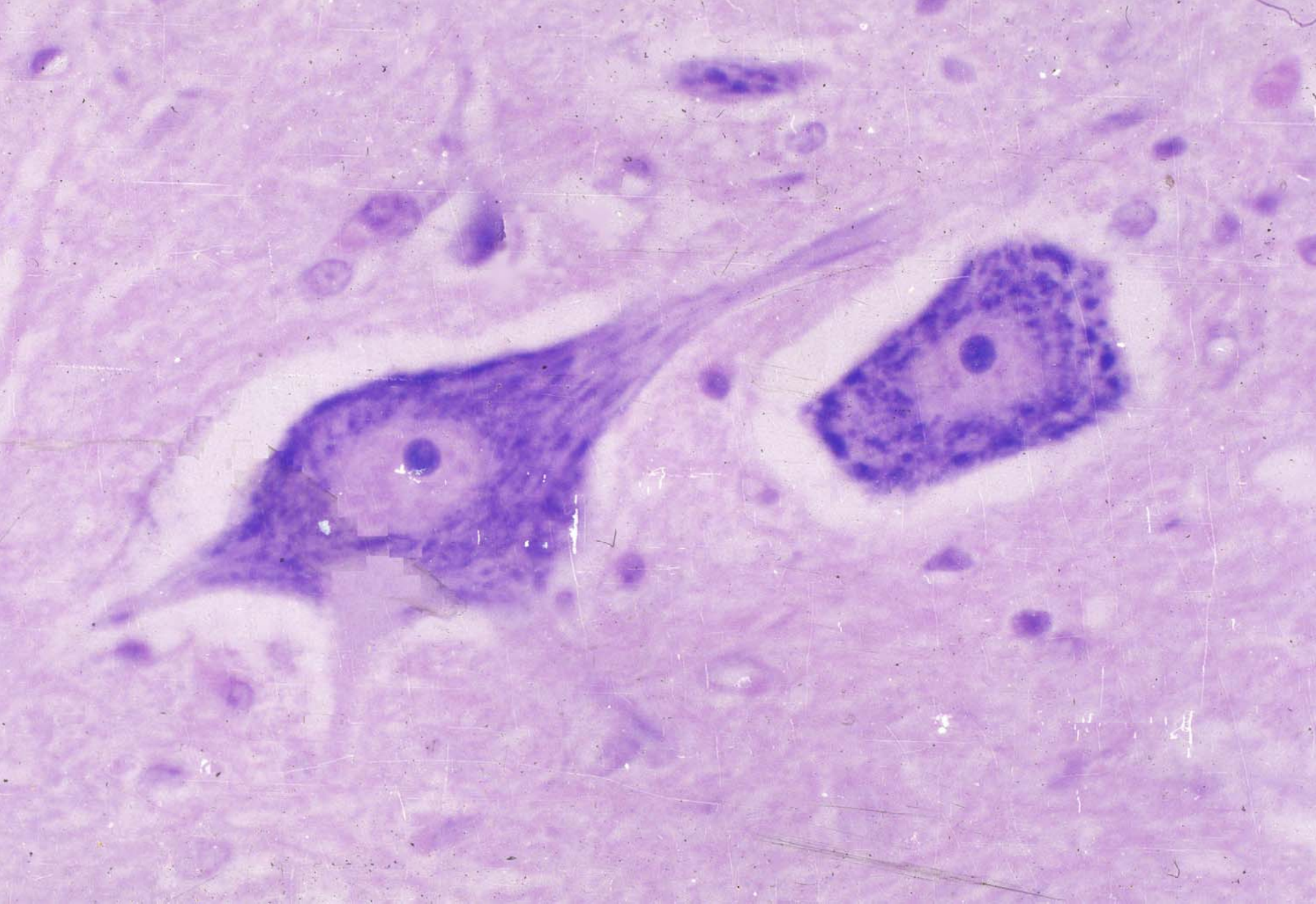
Date :

V. Summary:

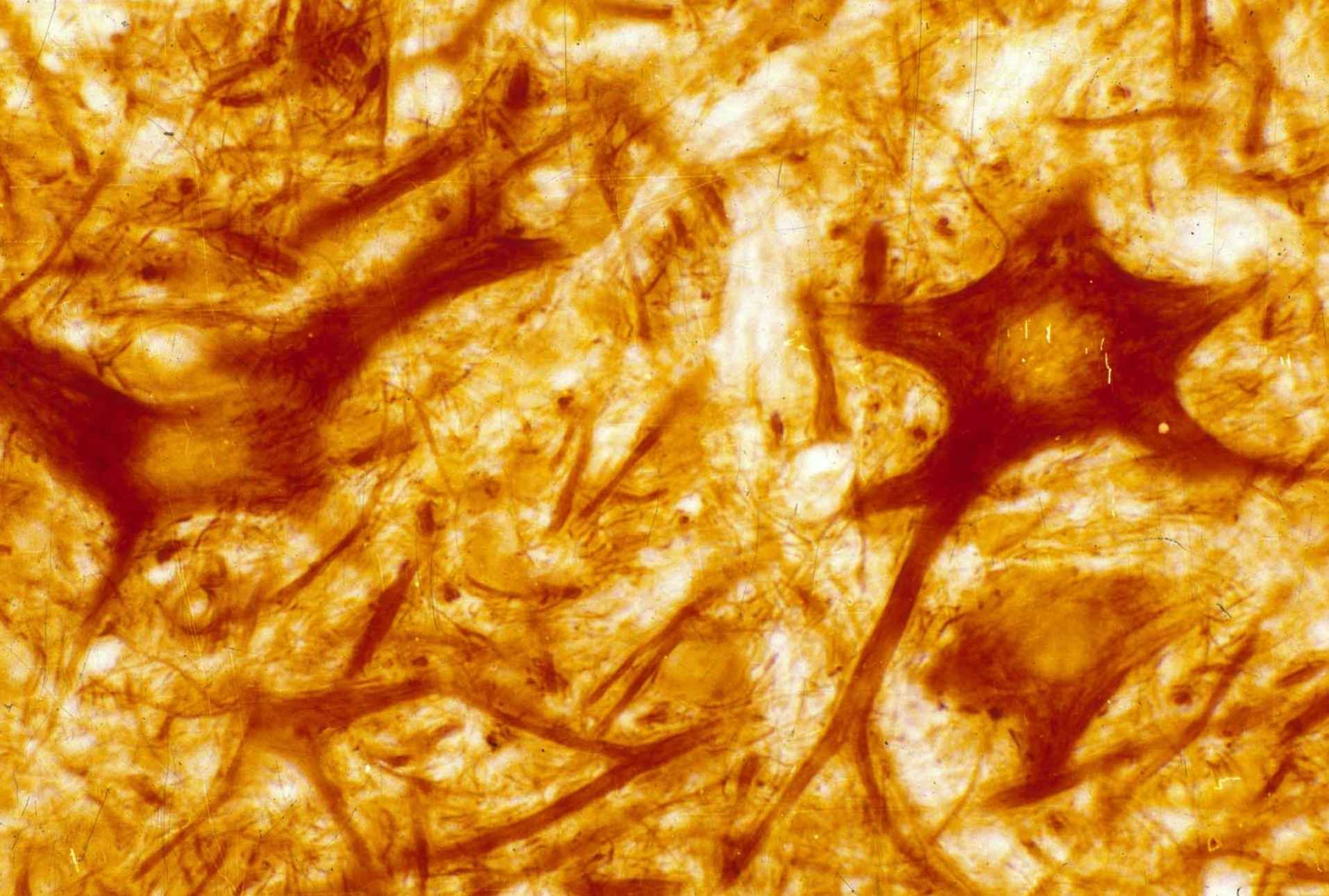
- The structure and function of neuron, nerve
- The type of neuroglia cell
- The ultra structure of synapse
- The structure and type of nerve fiber
- The structure of motor end plate



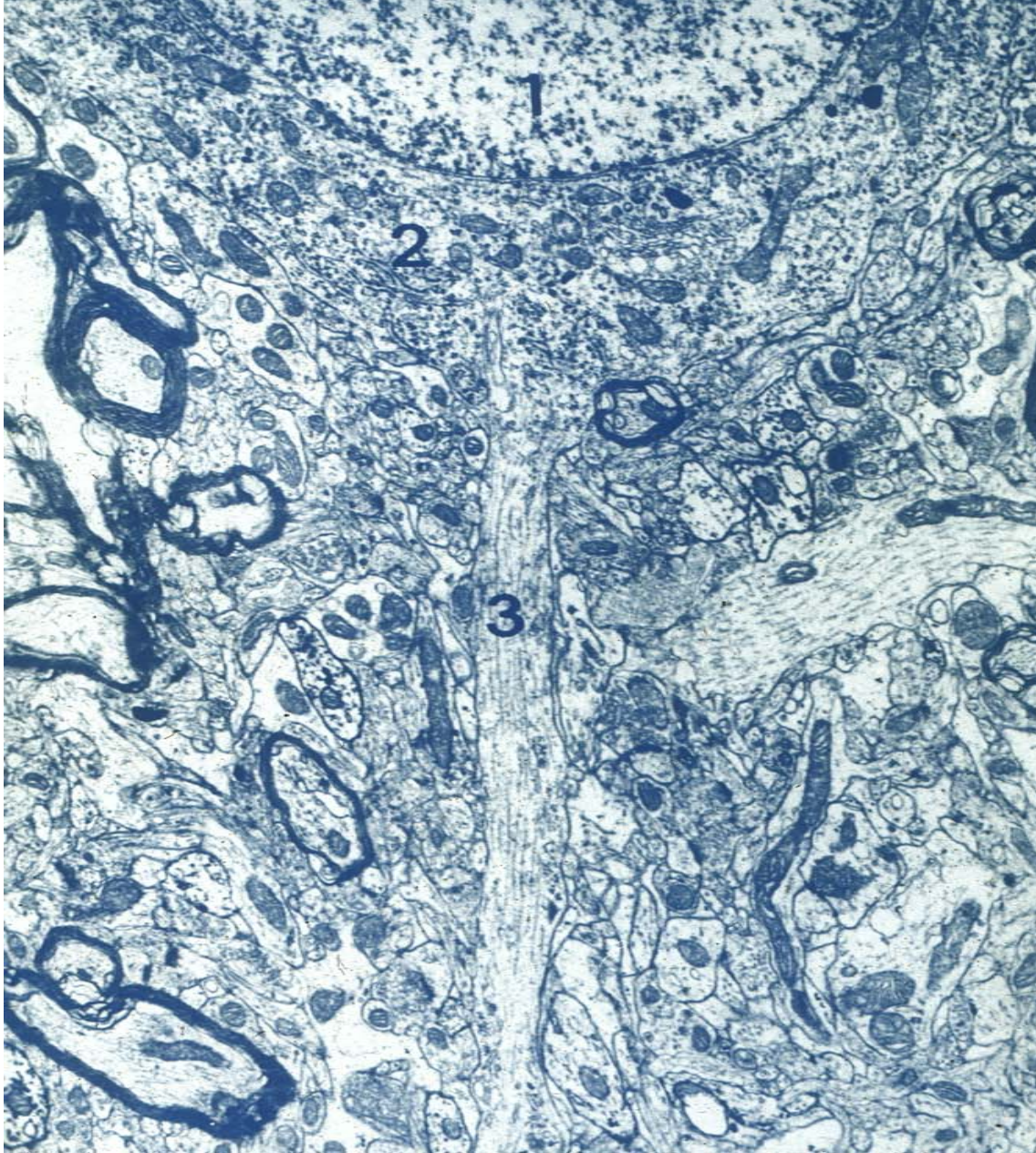
spinal cord



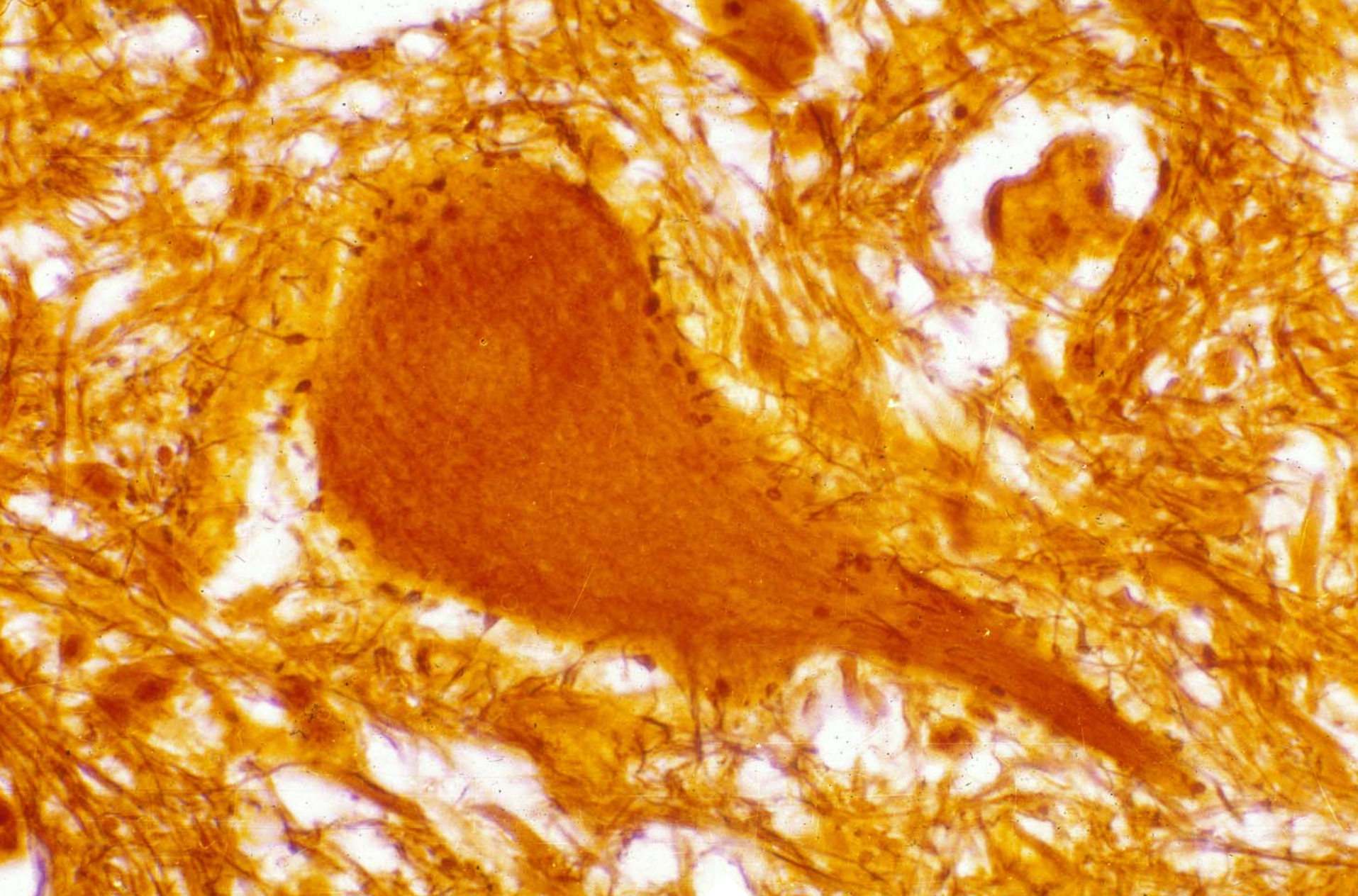
neuron



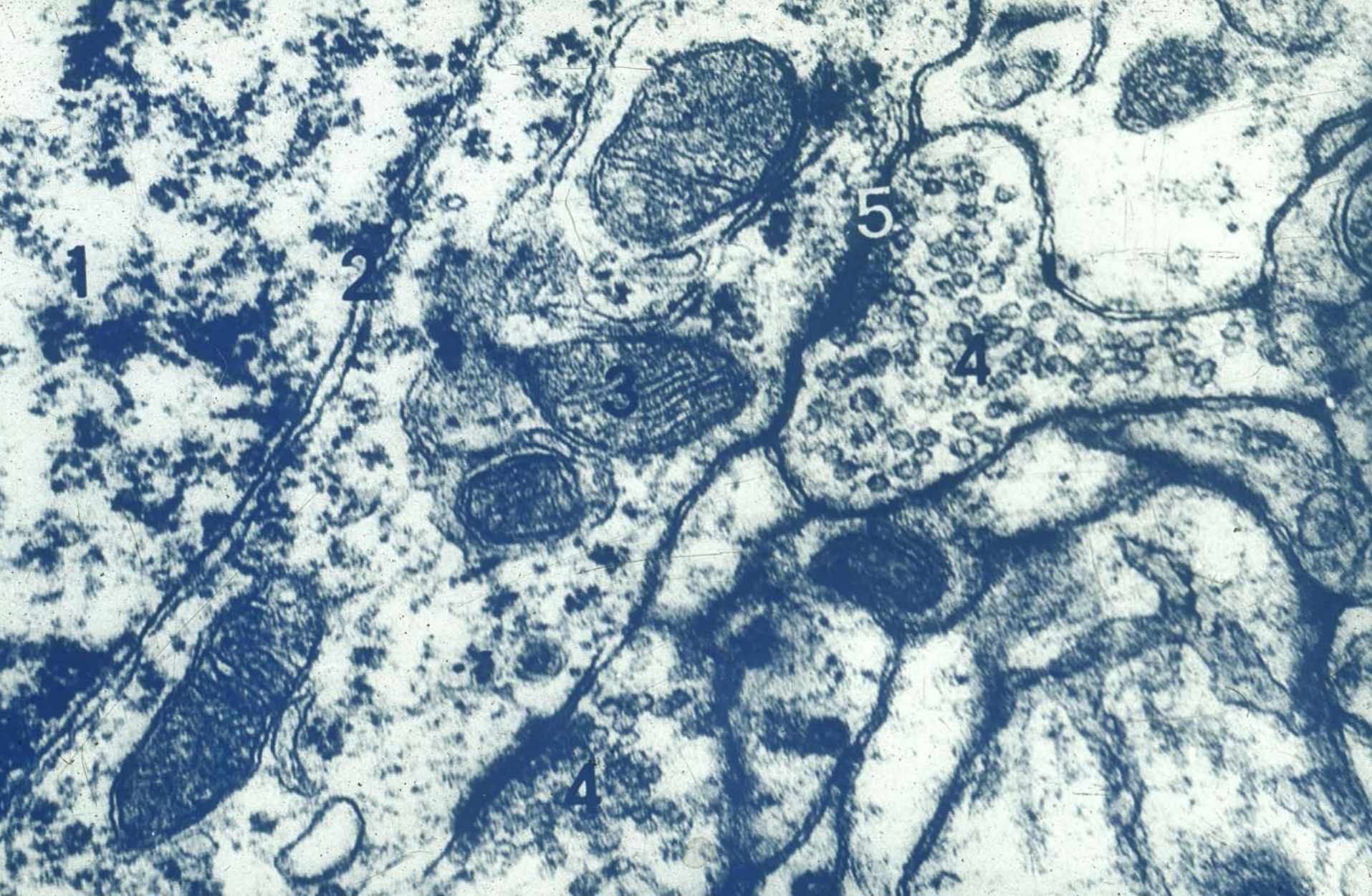
neuron



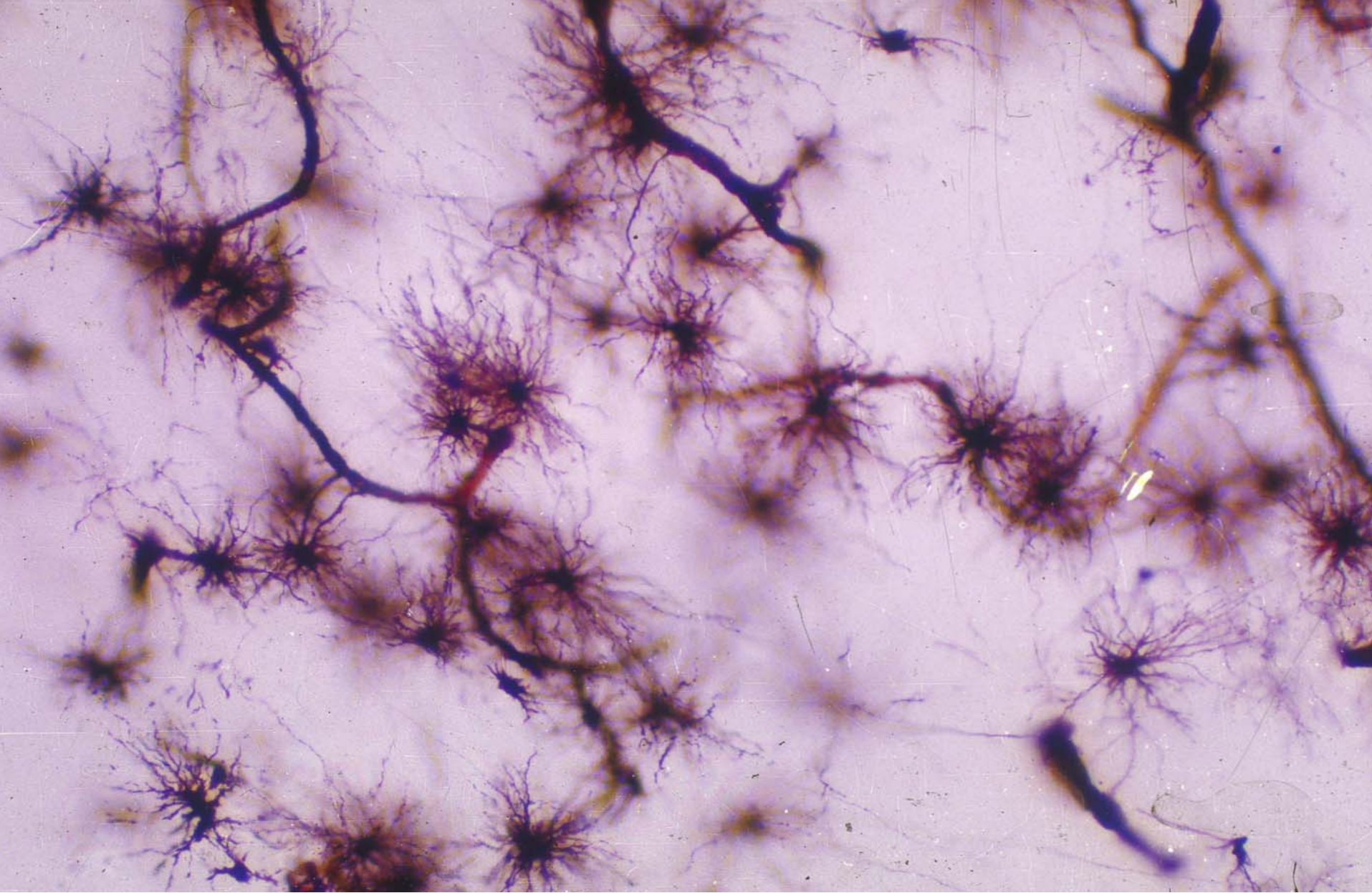
dendrite



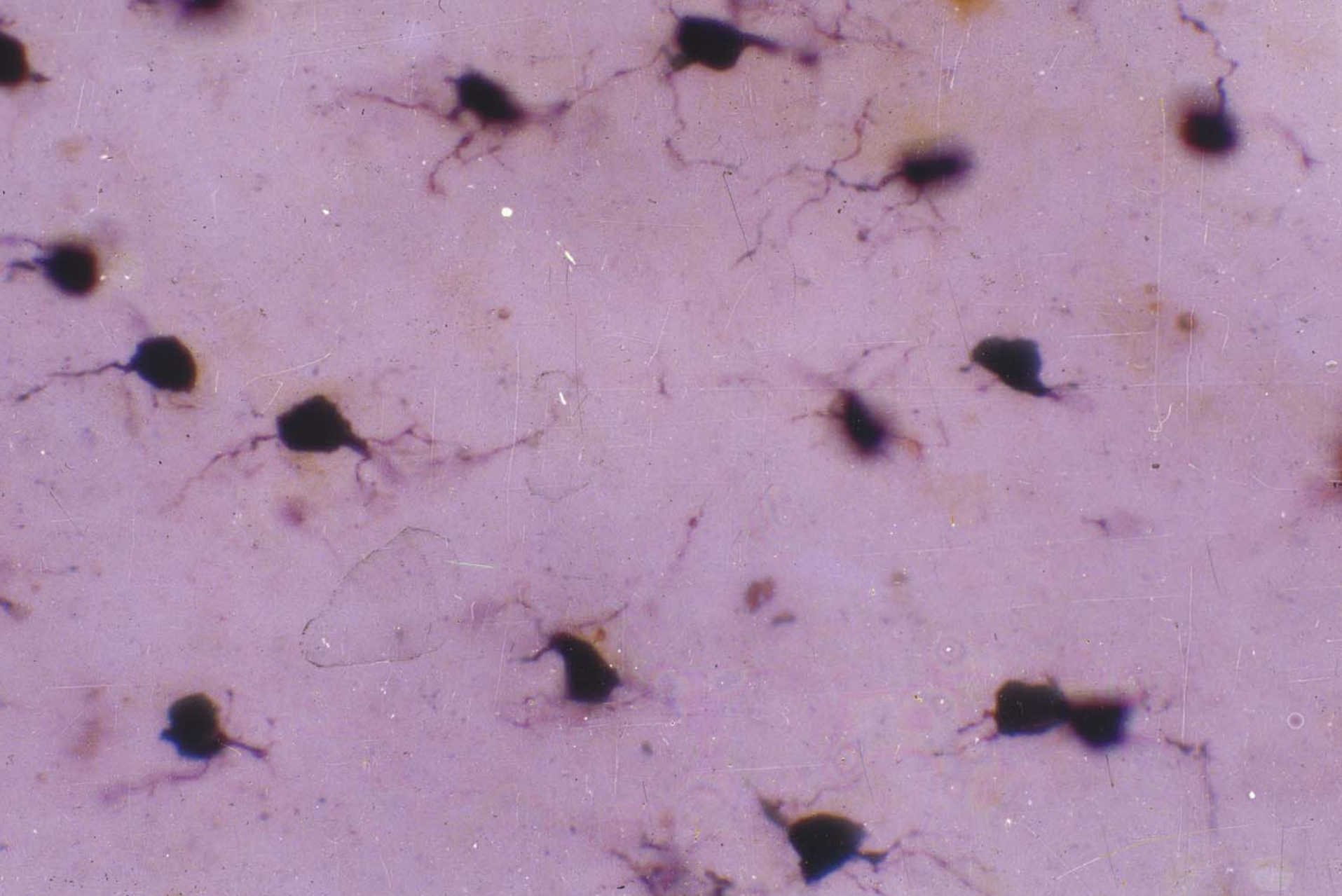
synapse



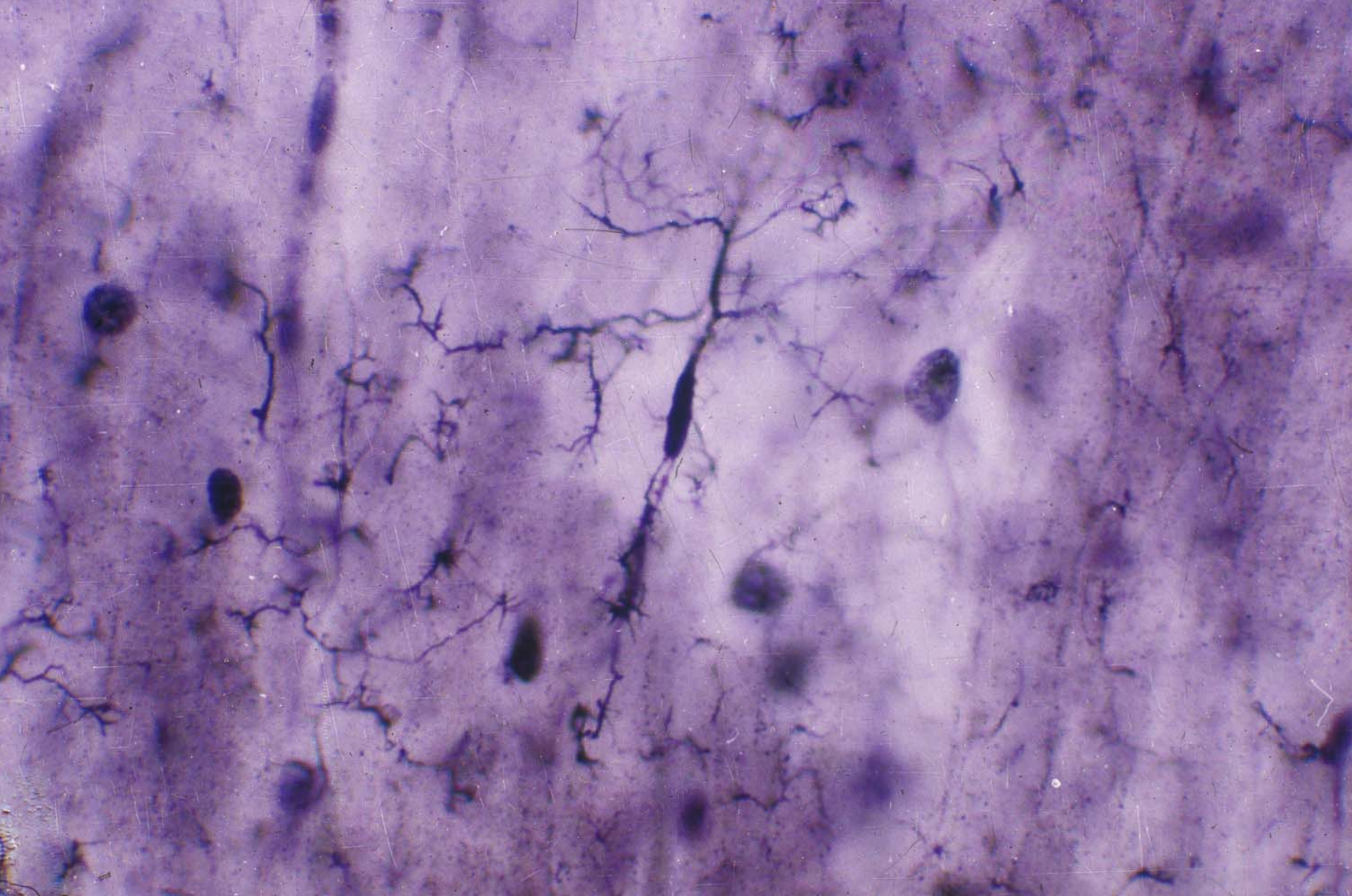
synapse



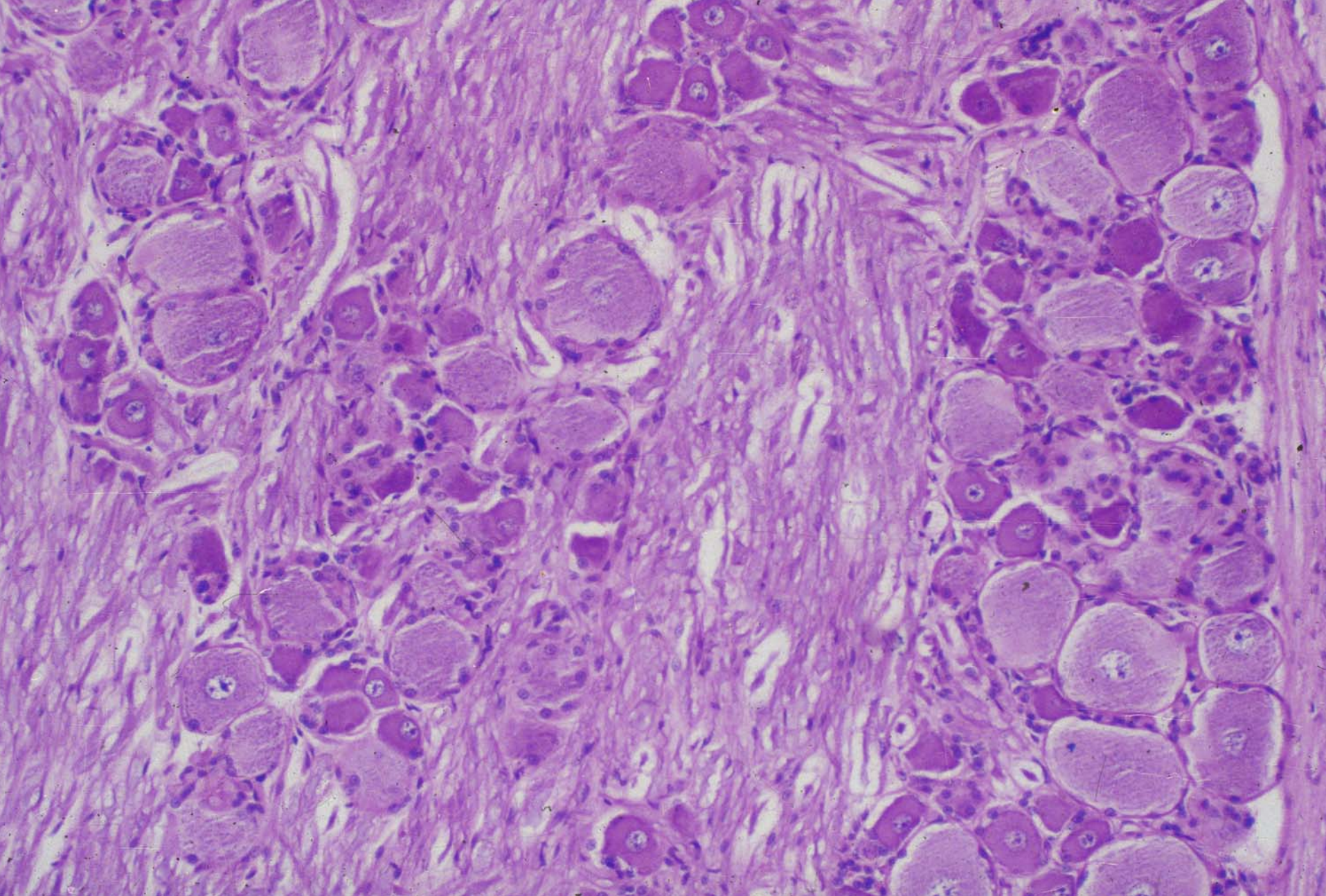
astrocyte



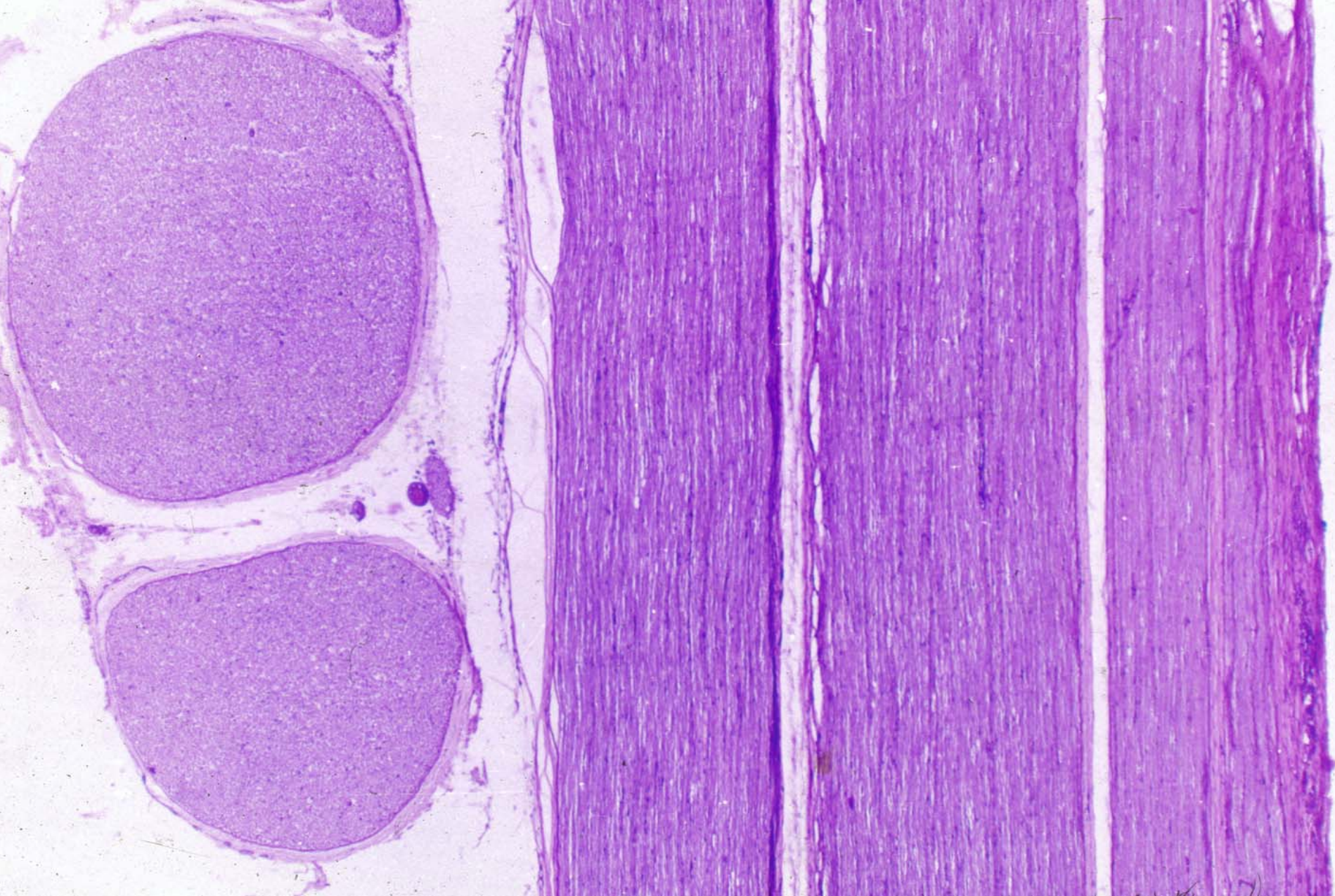
oligodendrocyte



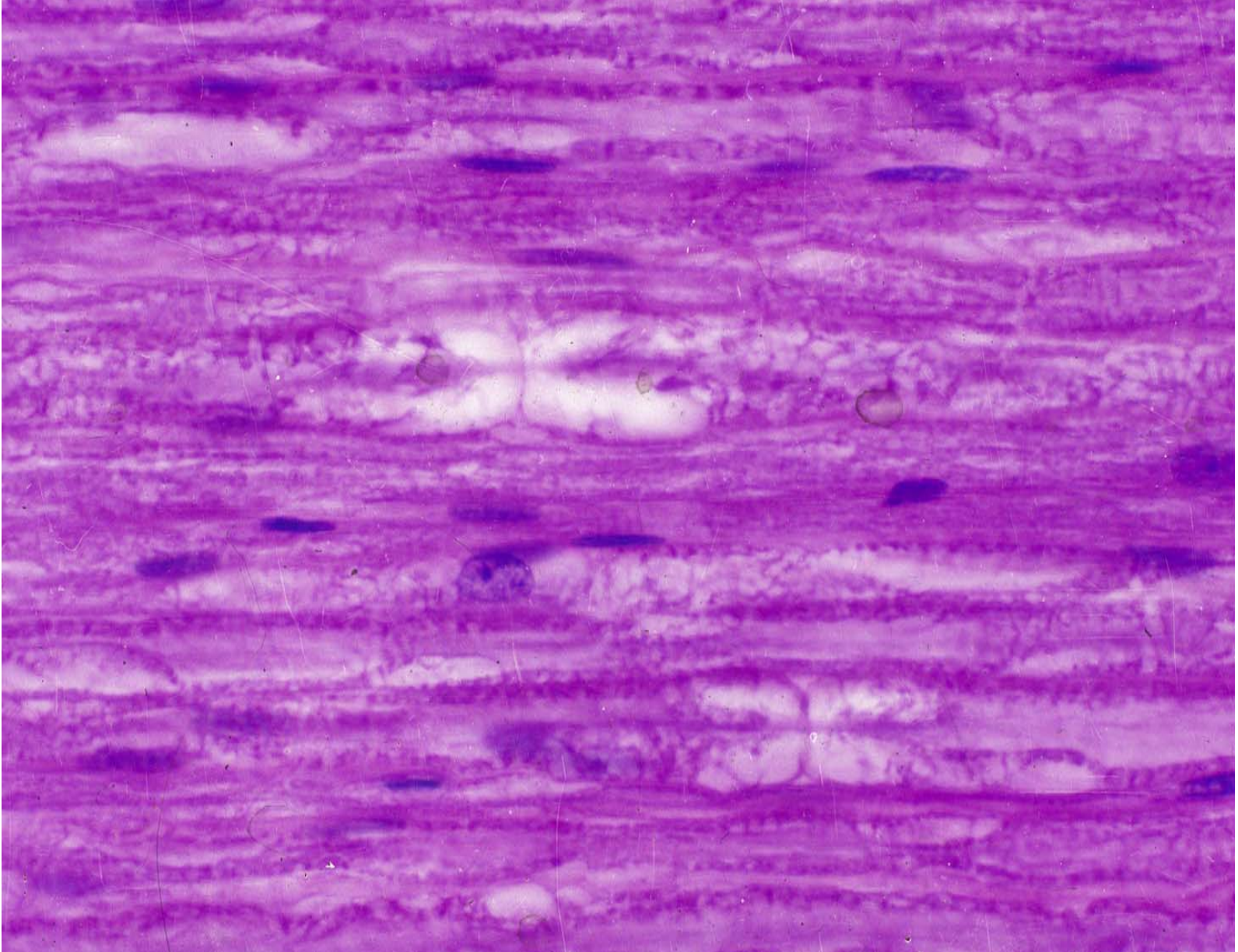
microglia



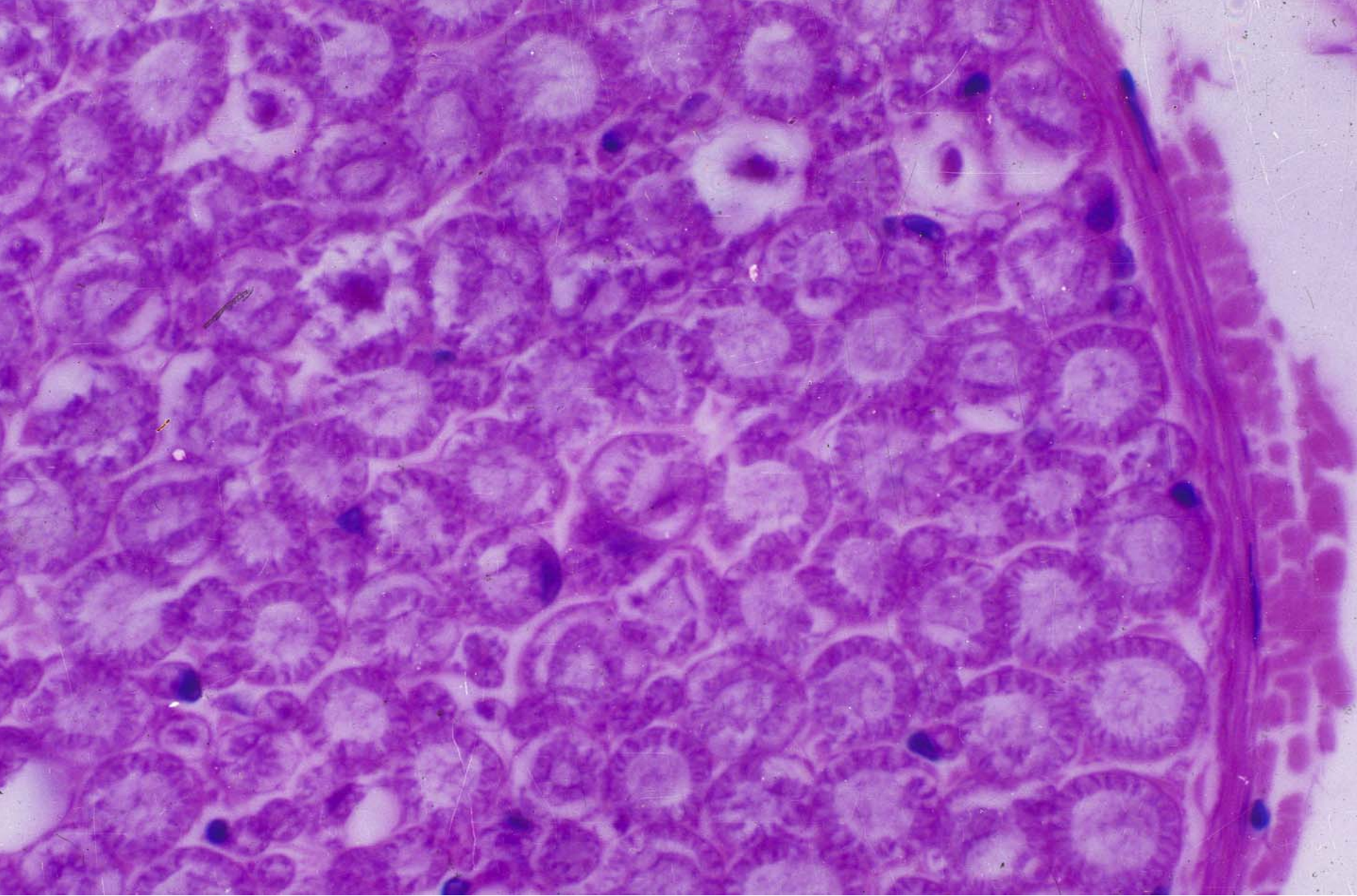
satellite cell



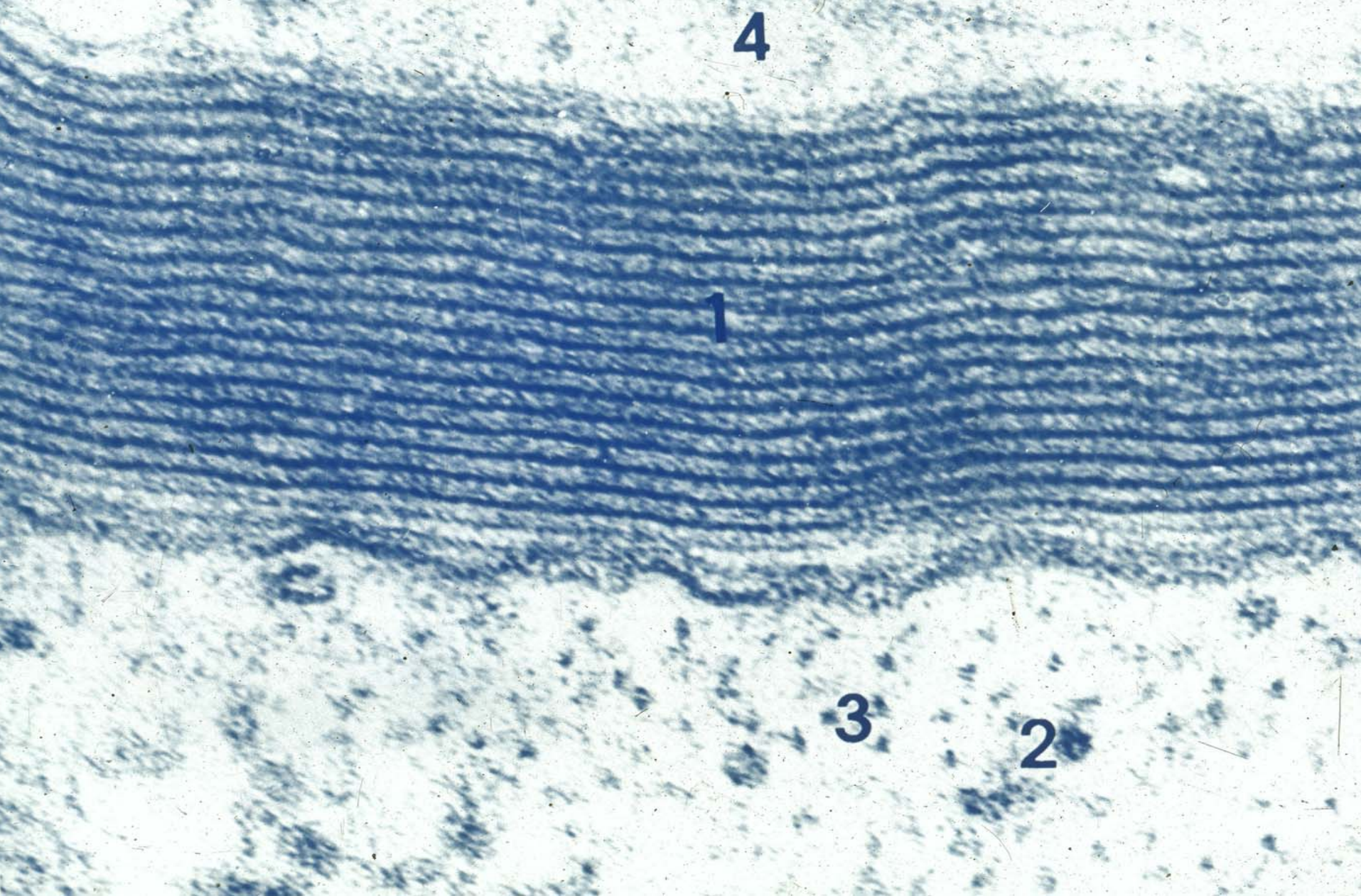
nerve



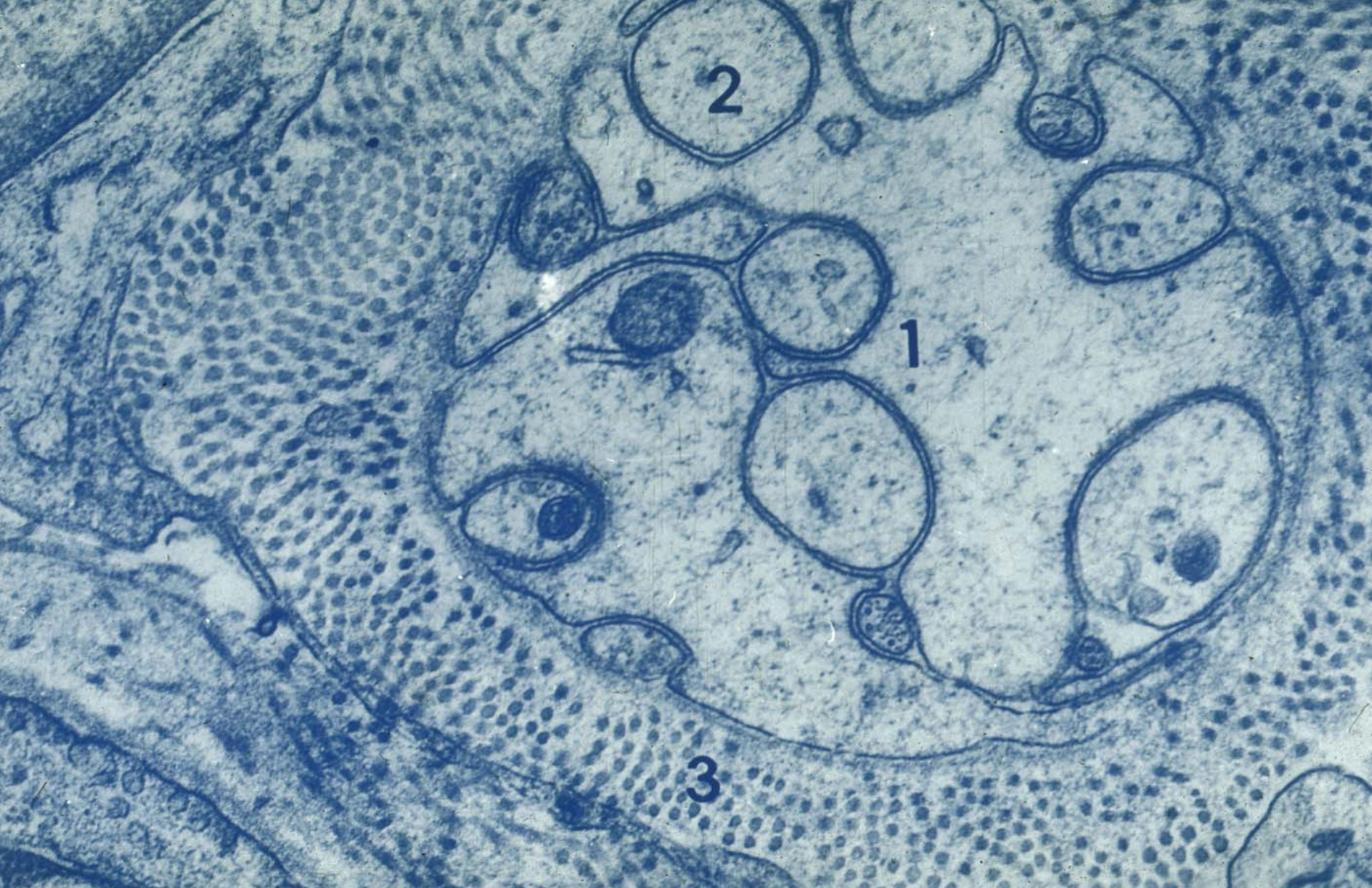
myelinated nerve fiber



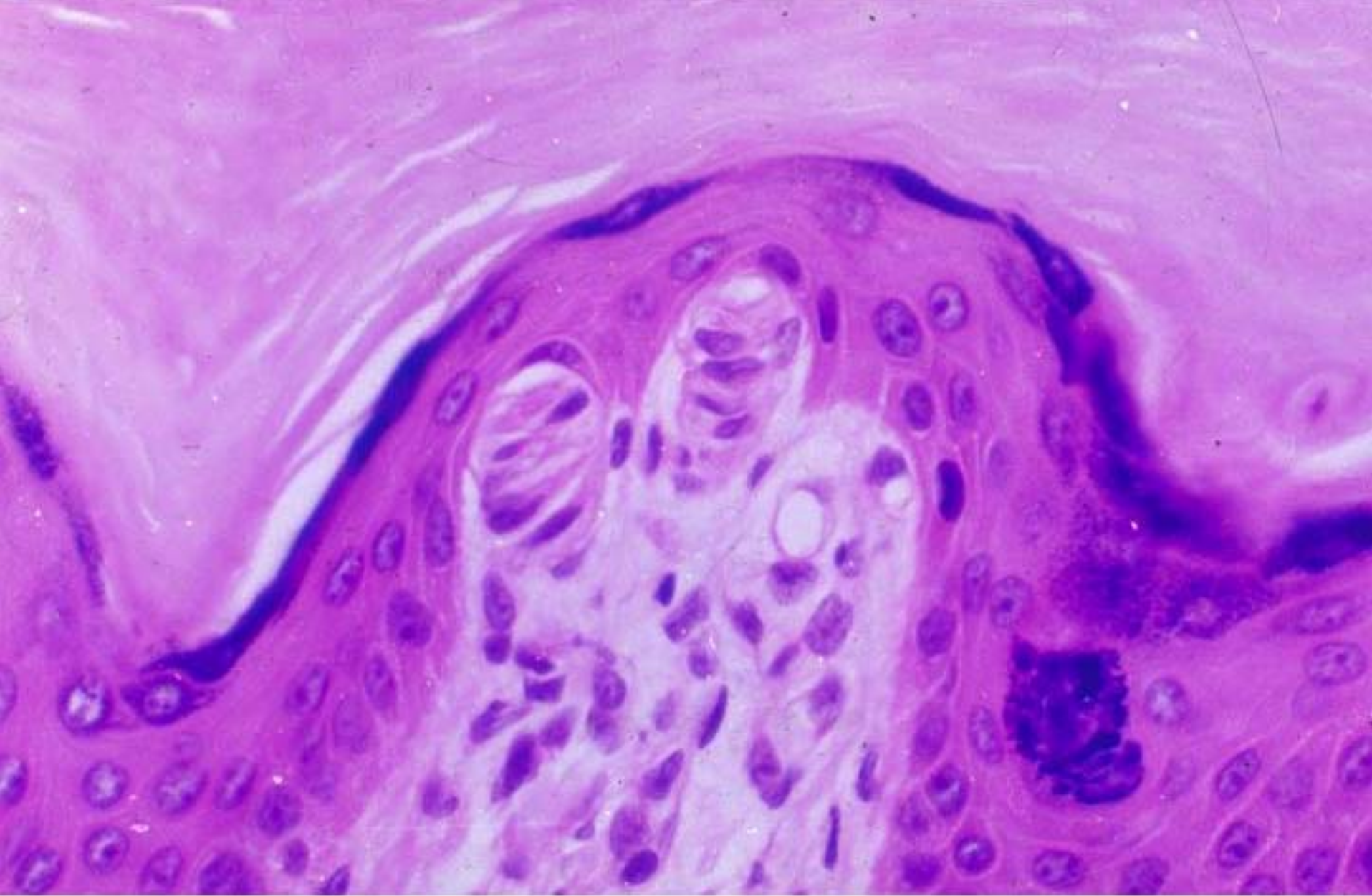
nerve fiber



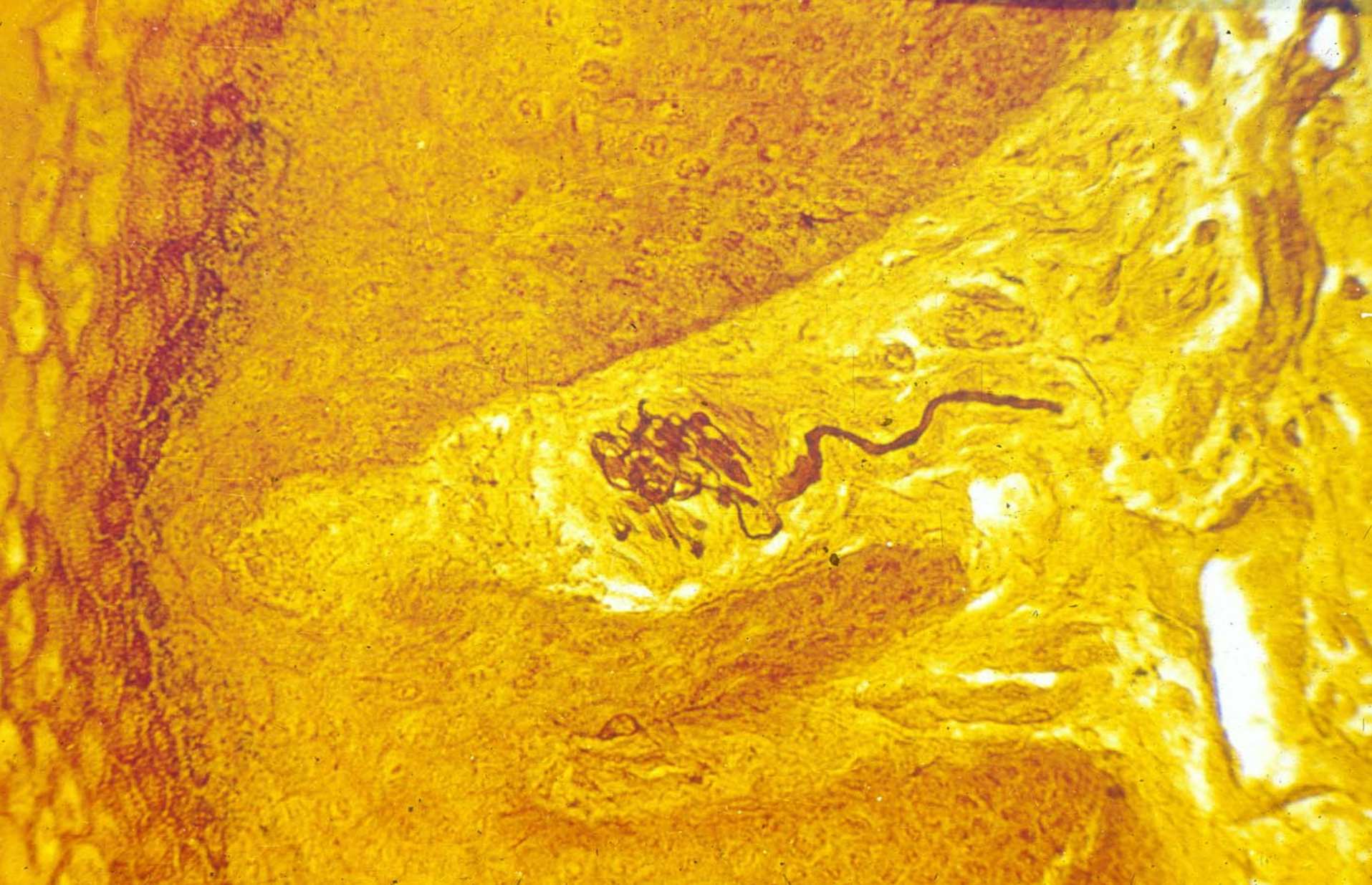
myelinated nerve fiber



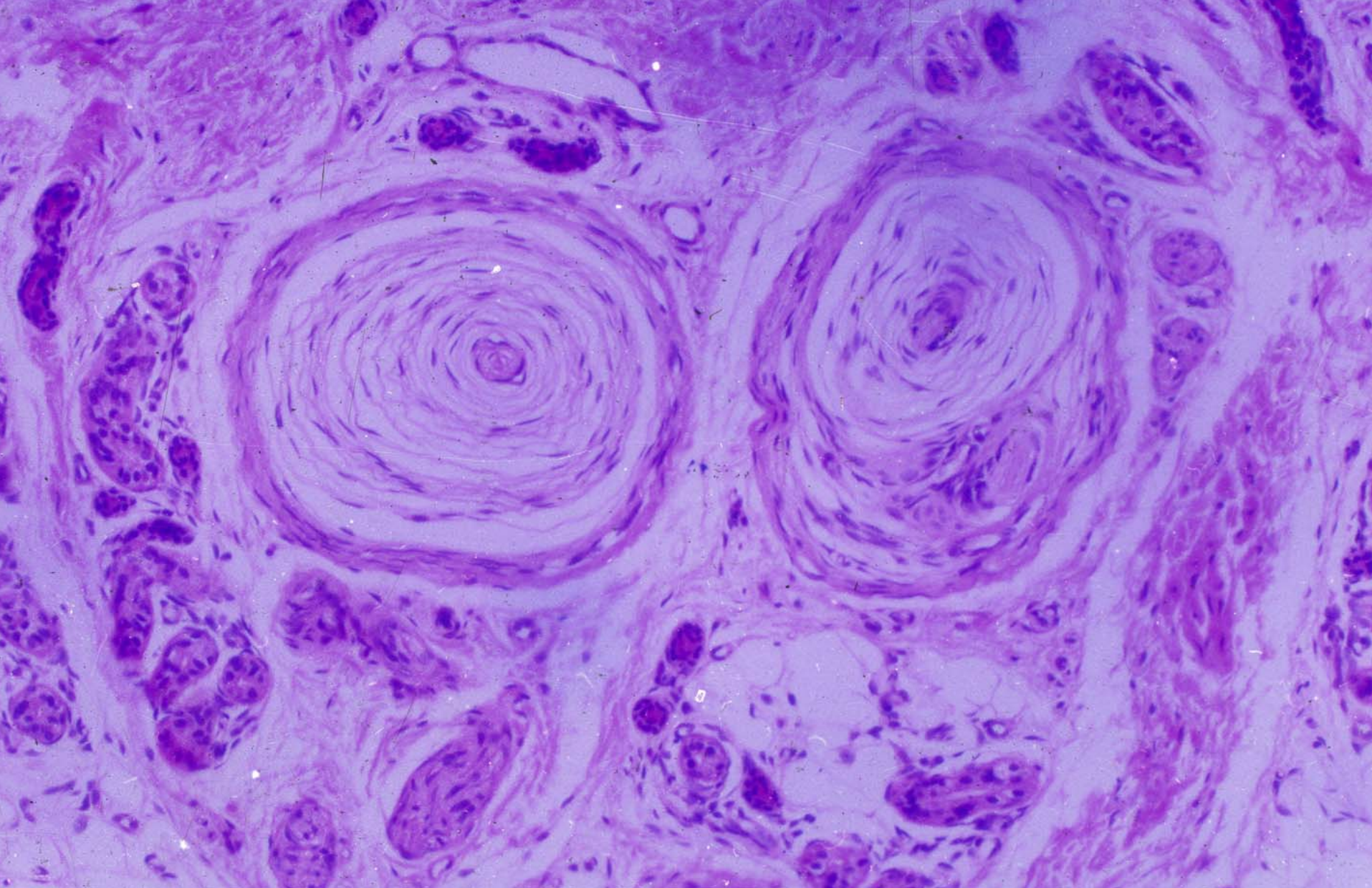
unmyelinated nerve fiber



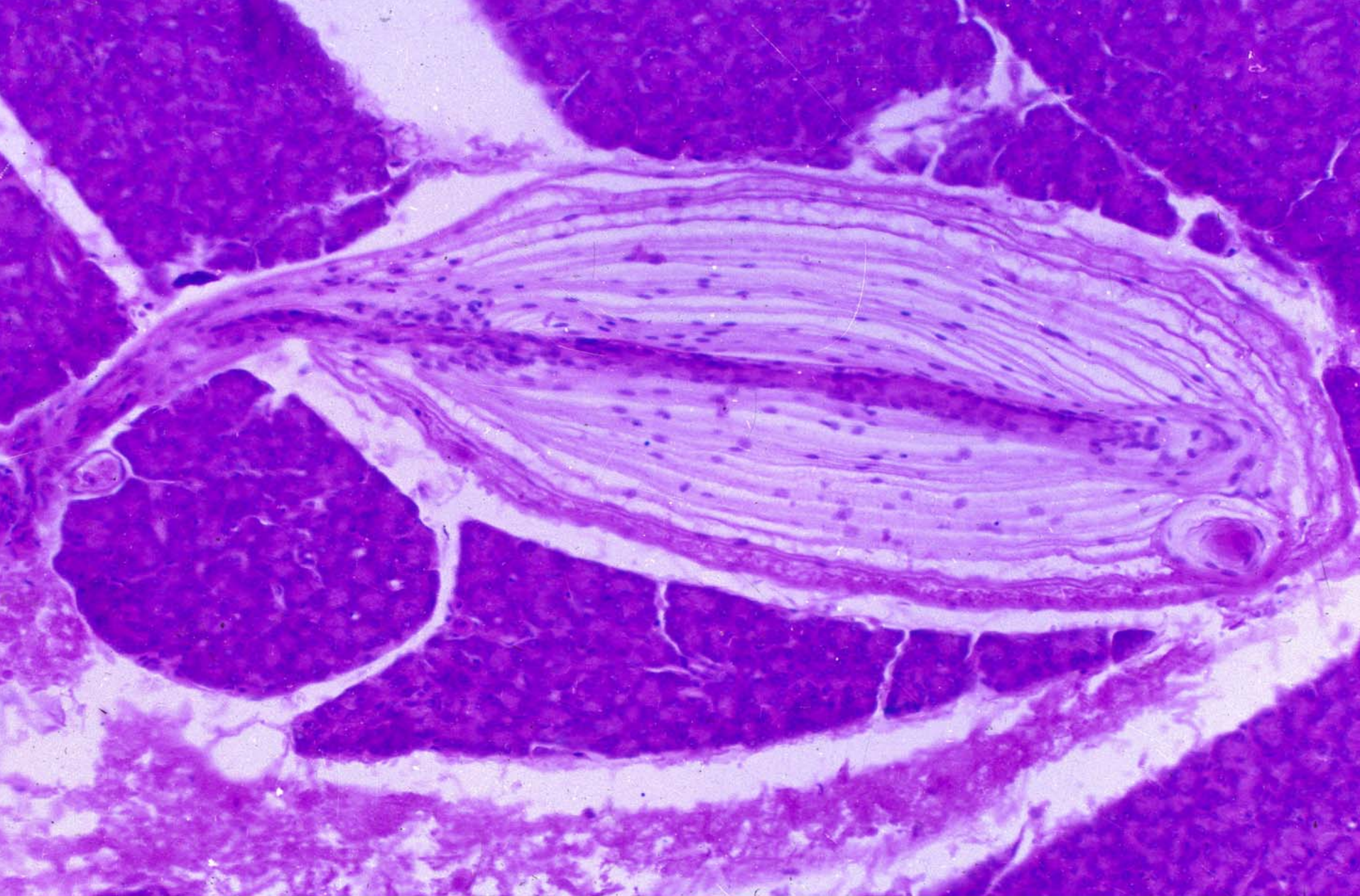
tactile corpuscle



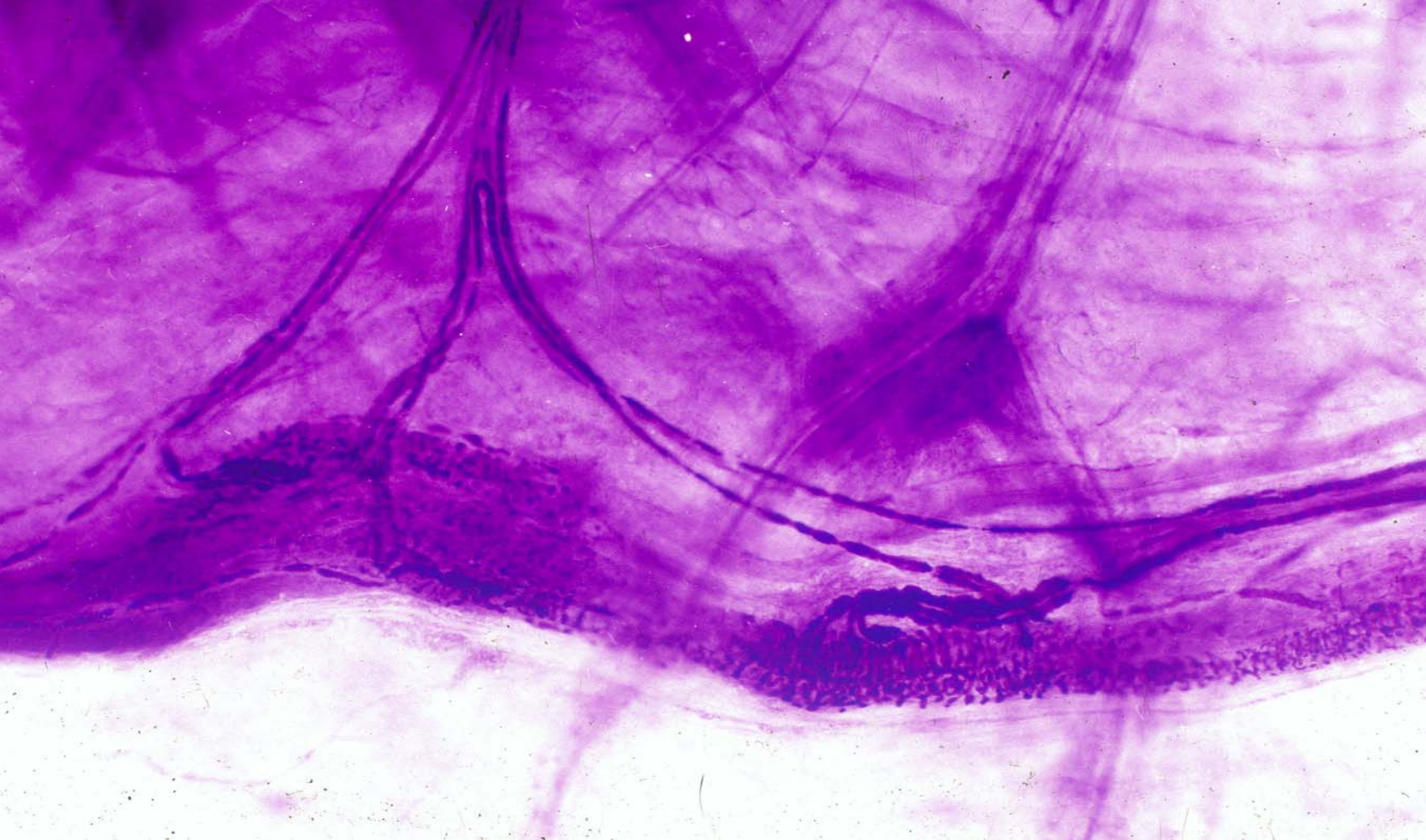
tactile corpuscle



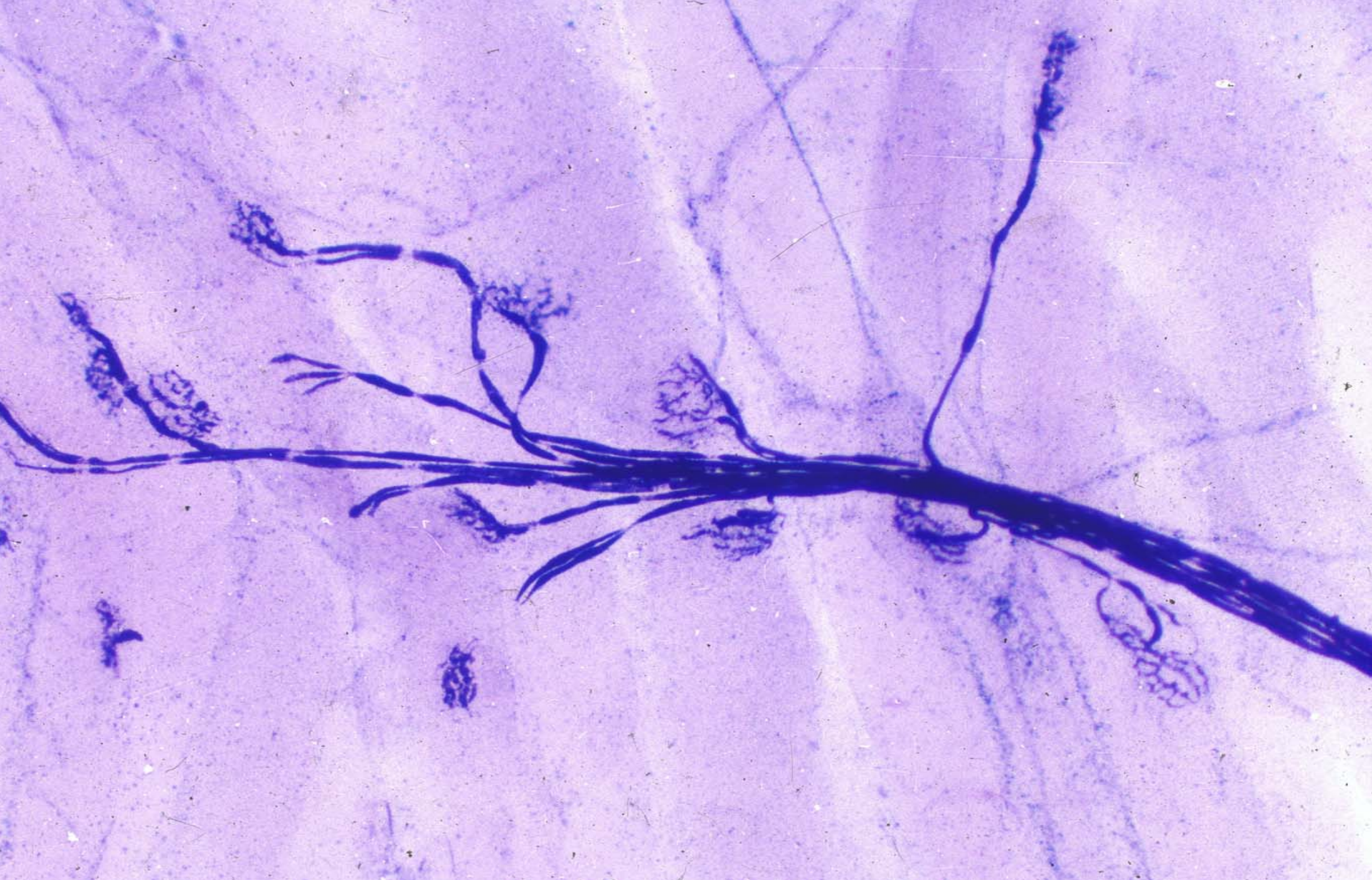
lamellar corpuscle



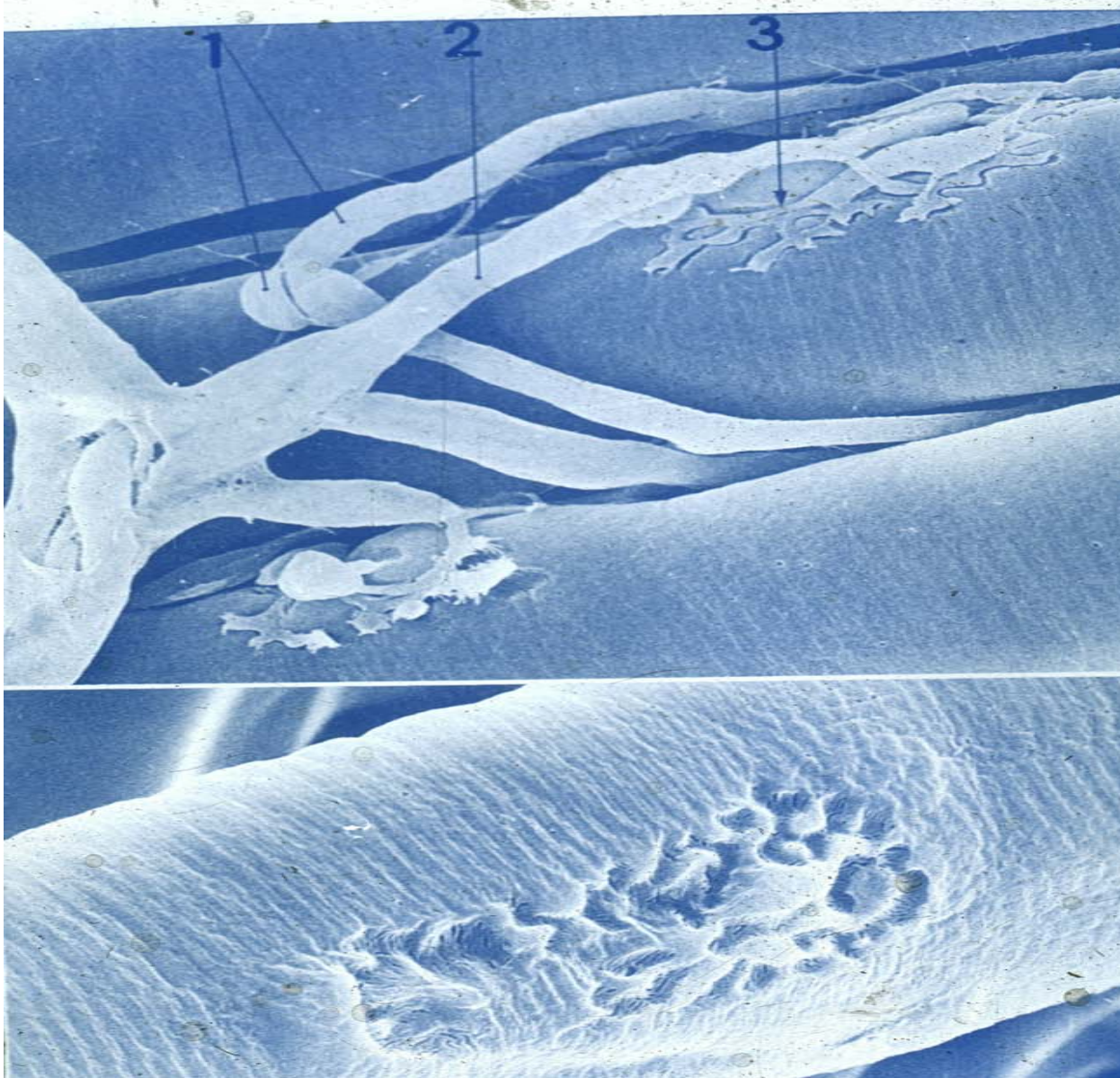
lamellar corpuscle



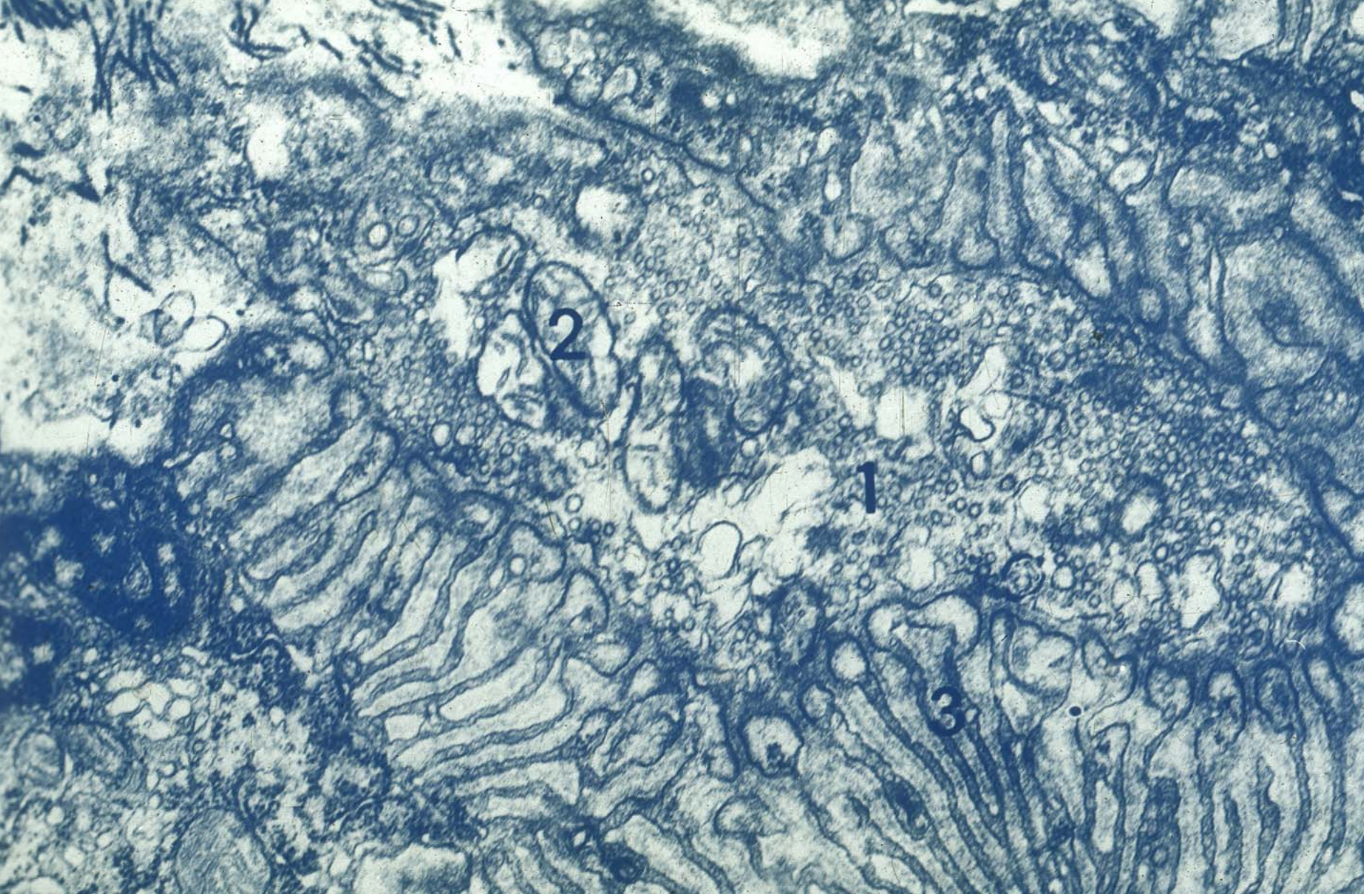
muscle spindle



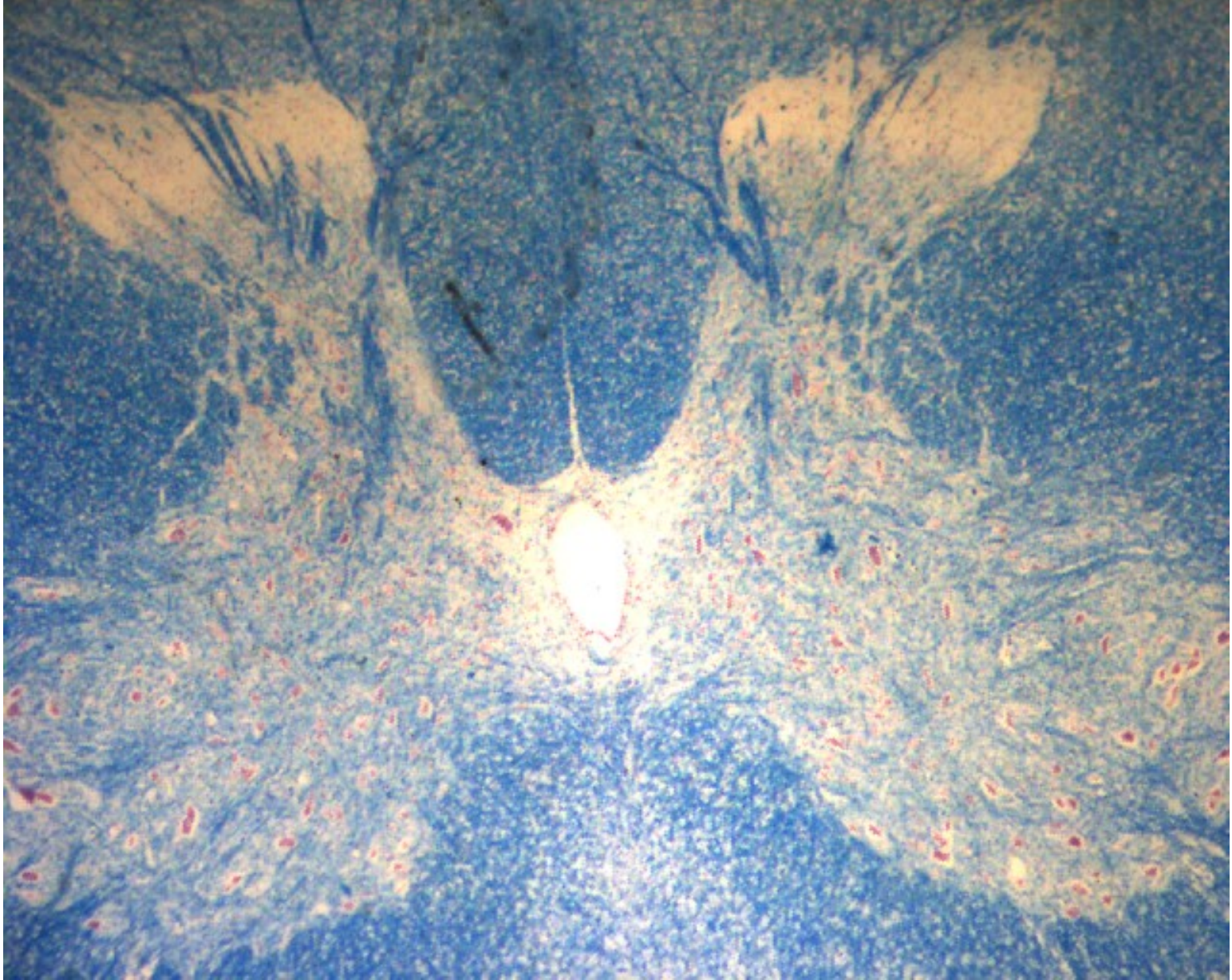
motor end plate



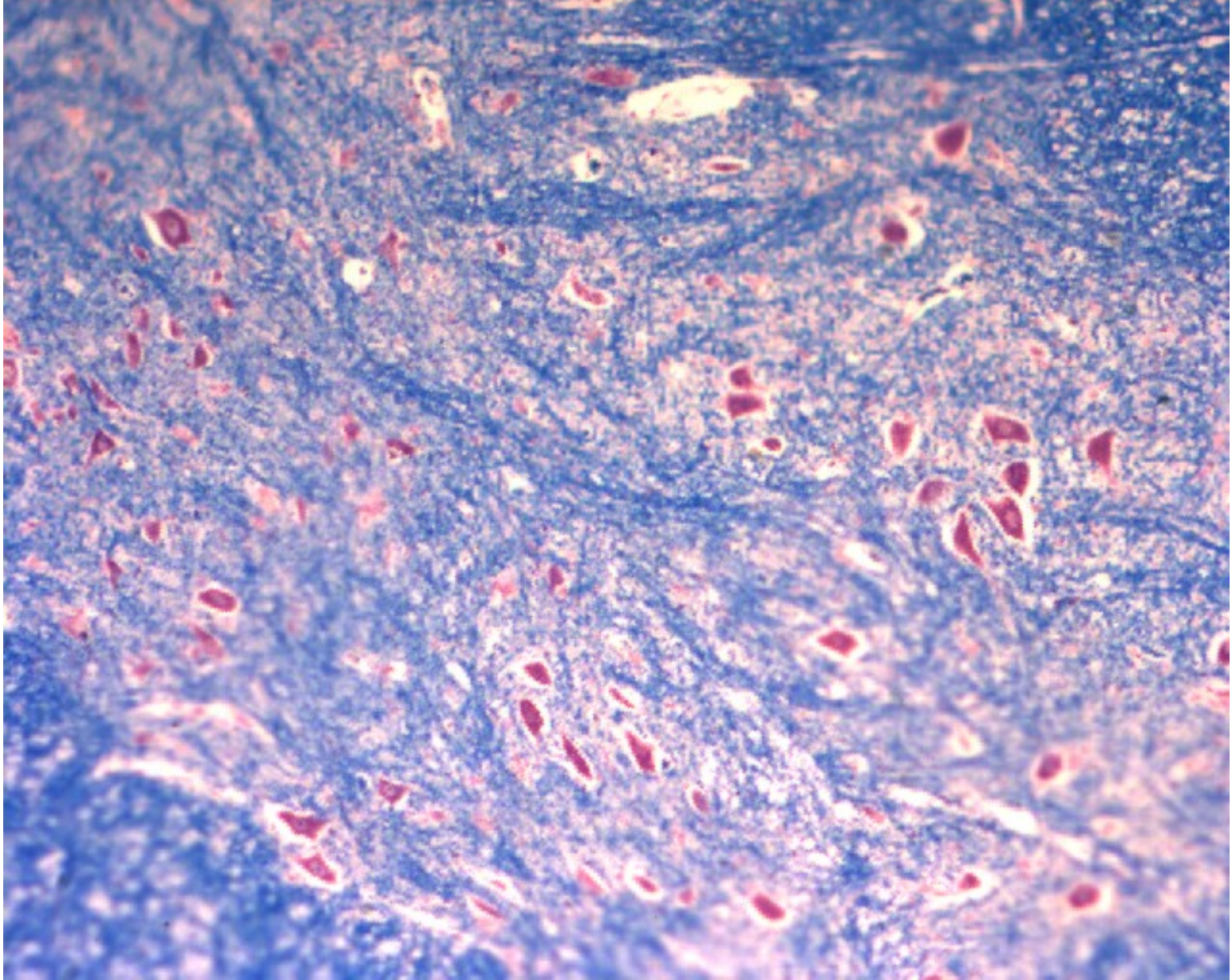
motor end plate



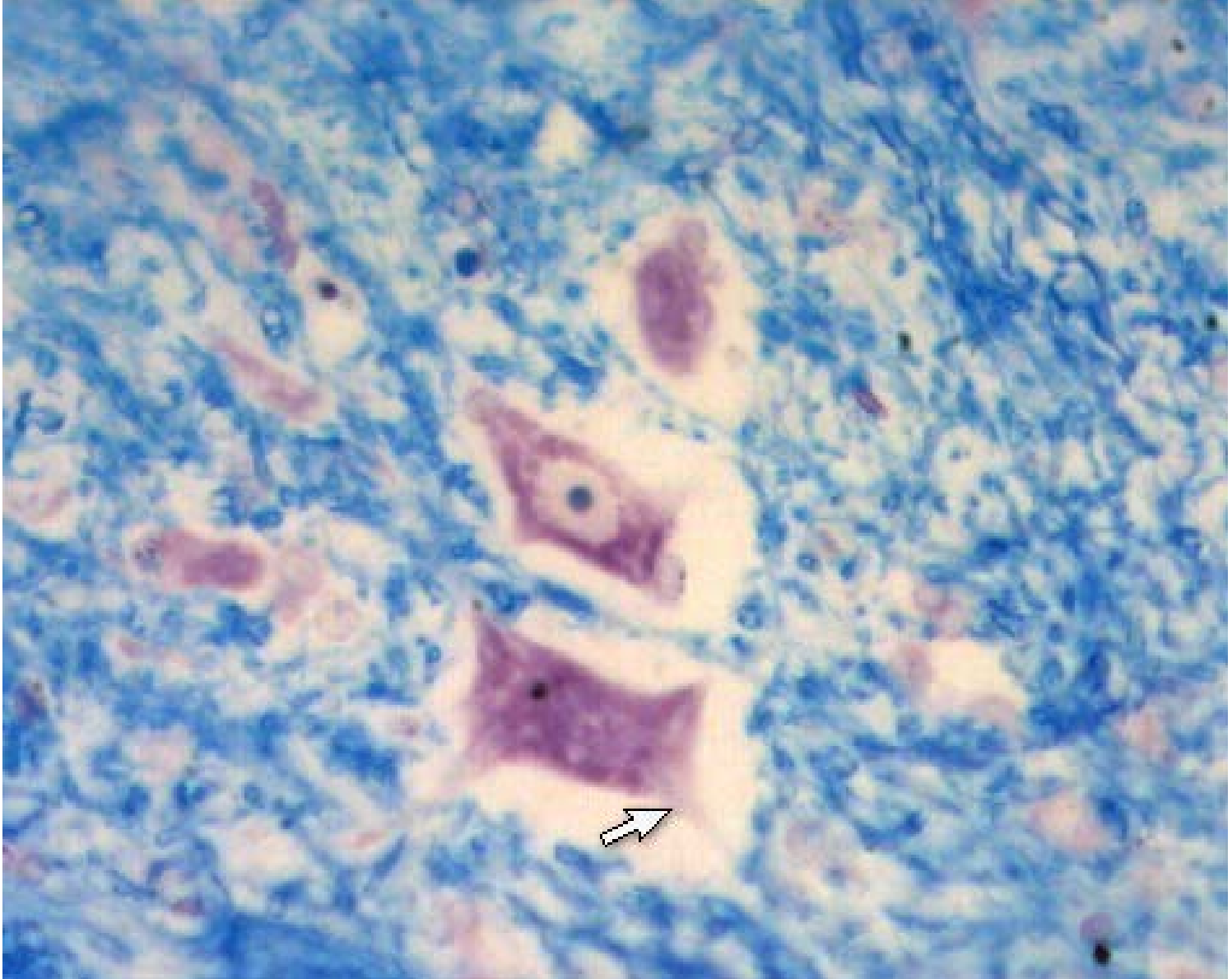
motor end plate



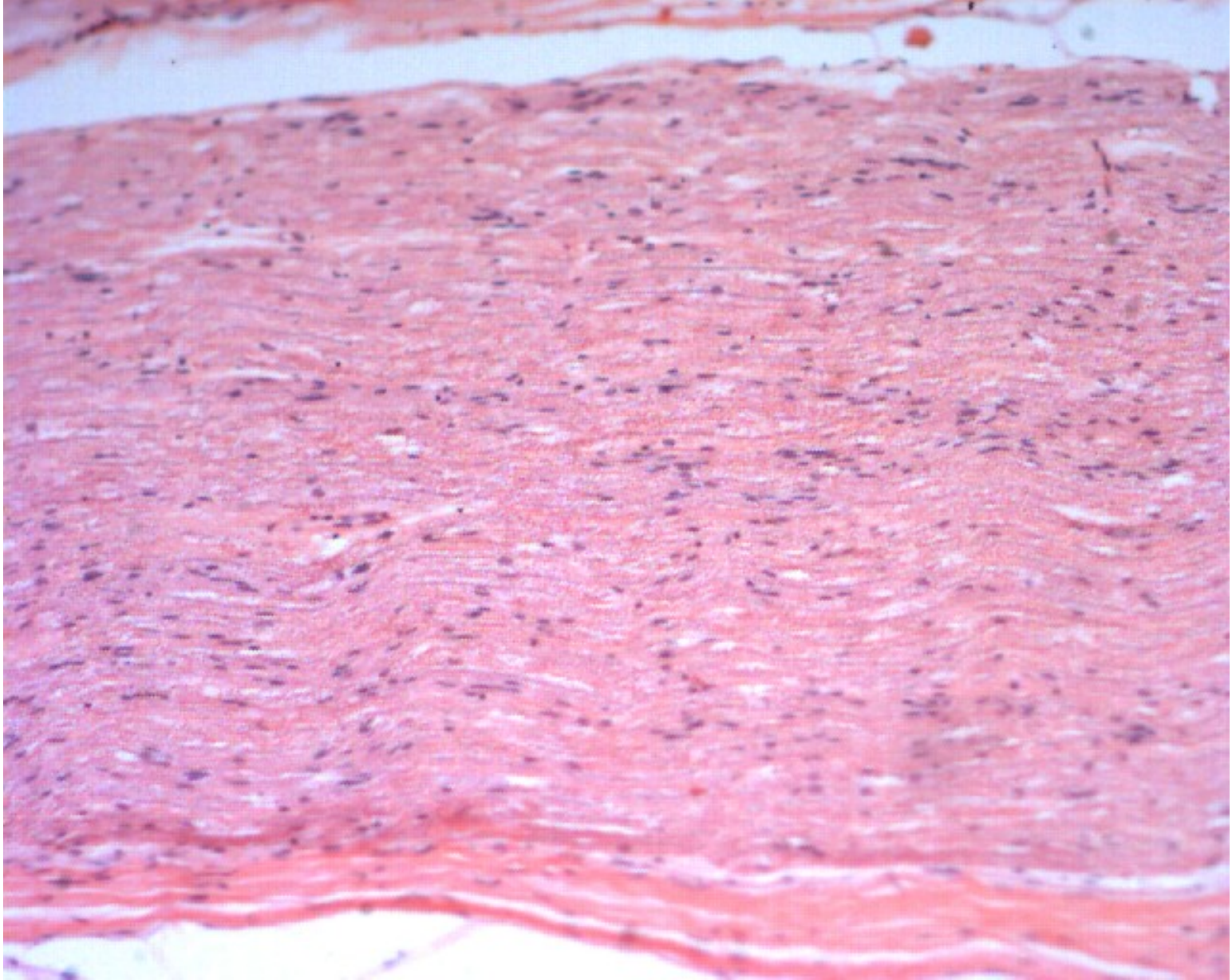
spinal cord



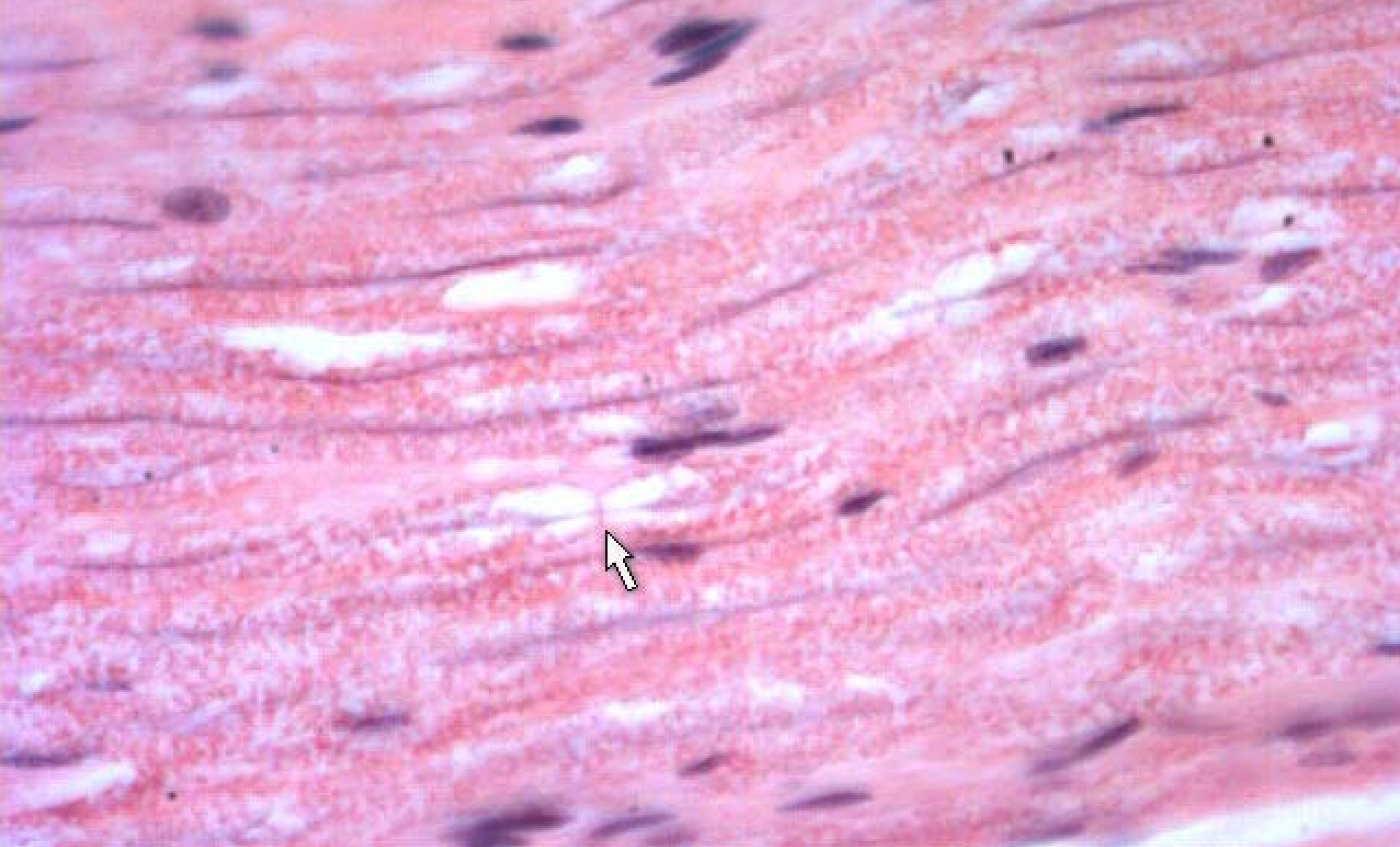
neuron



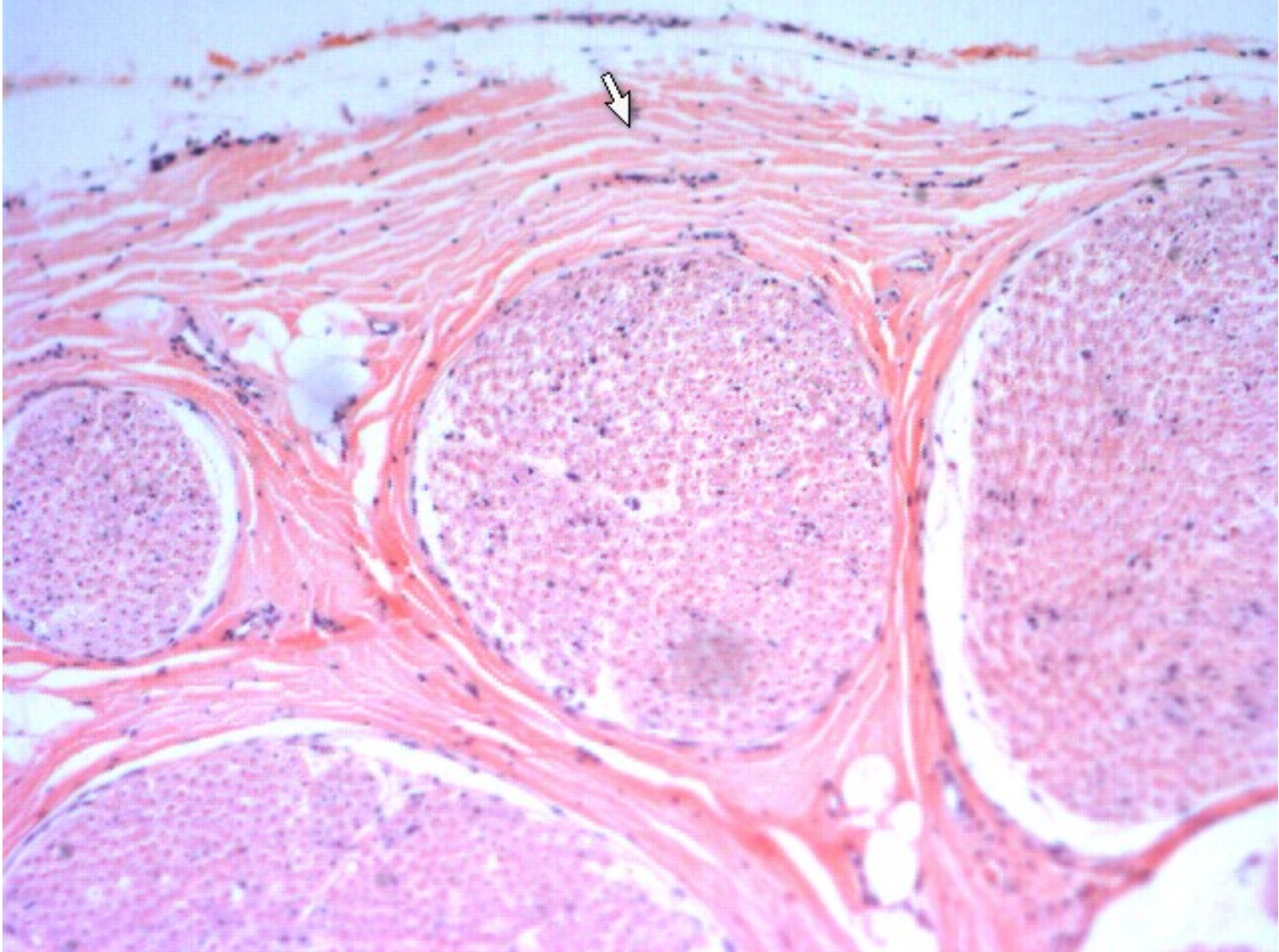
neuron



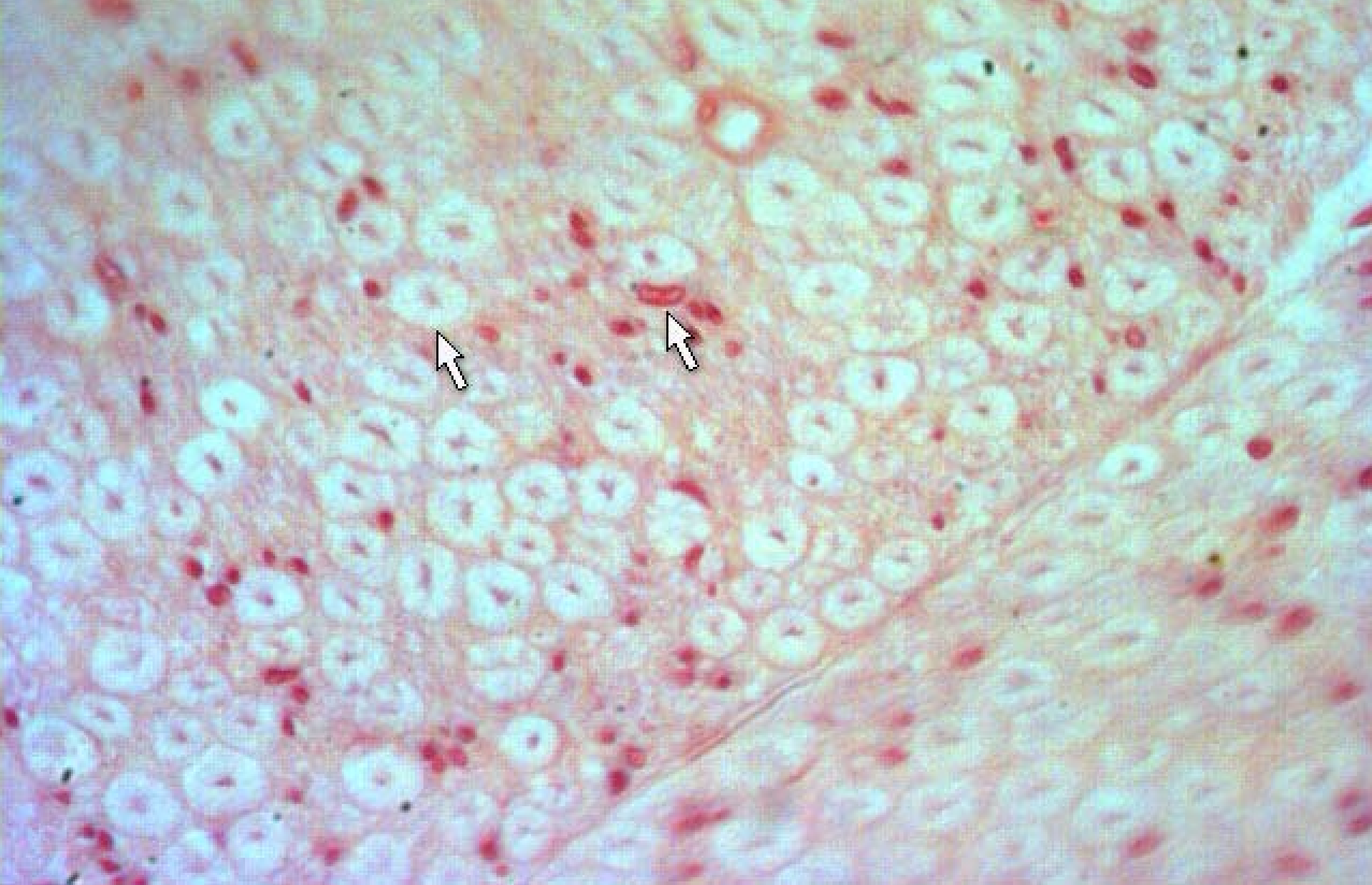
nerve



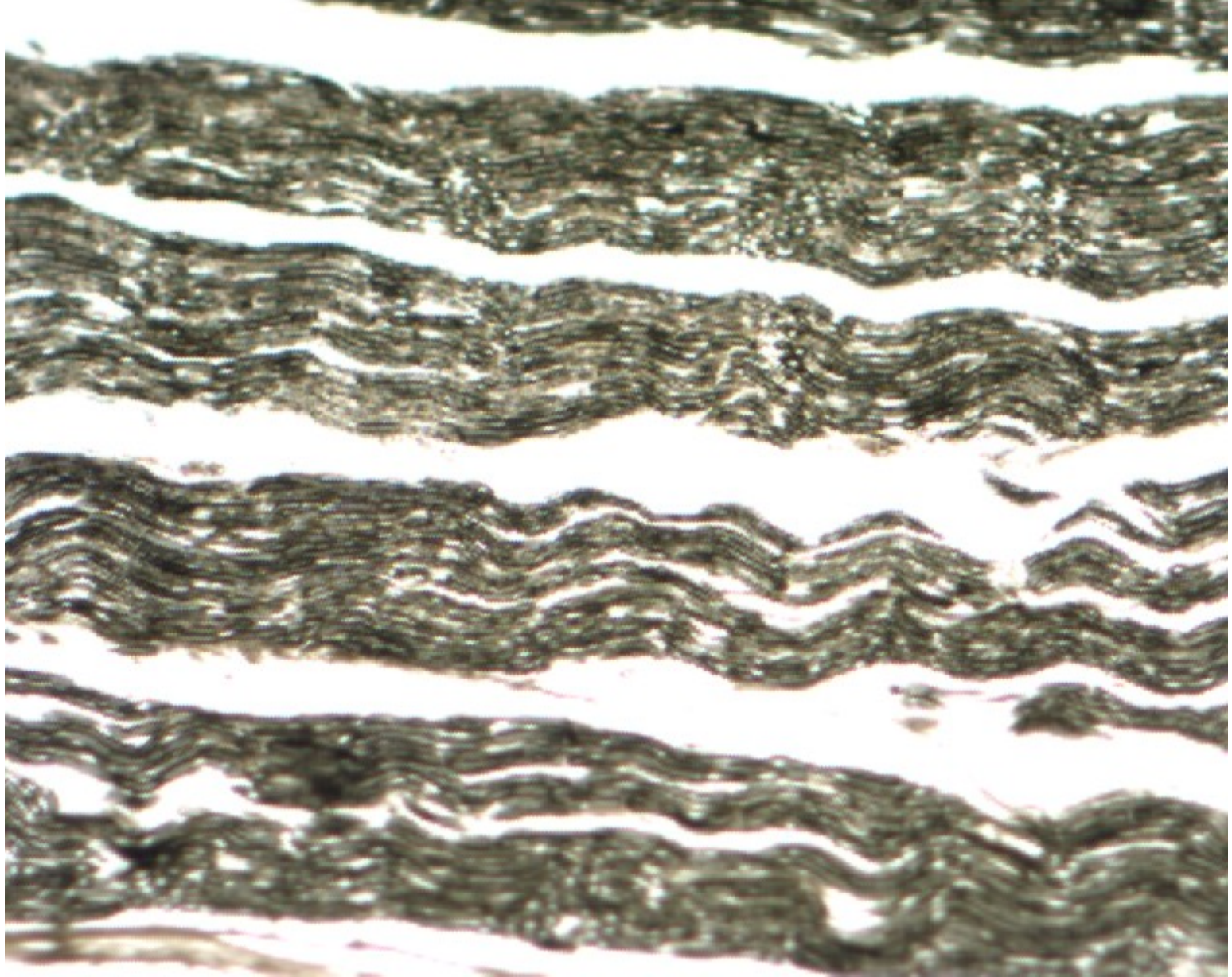
Ranvier node




nerve



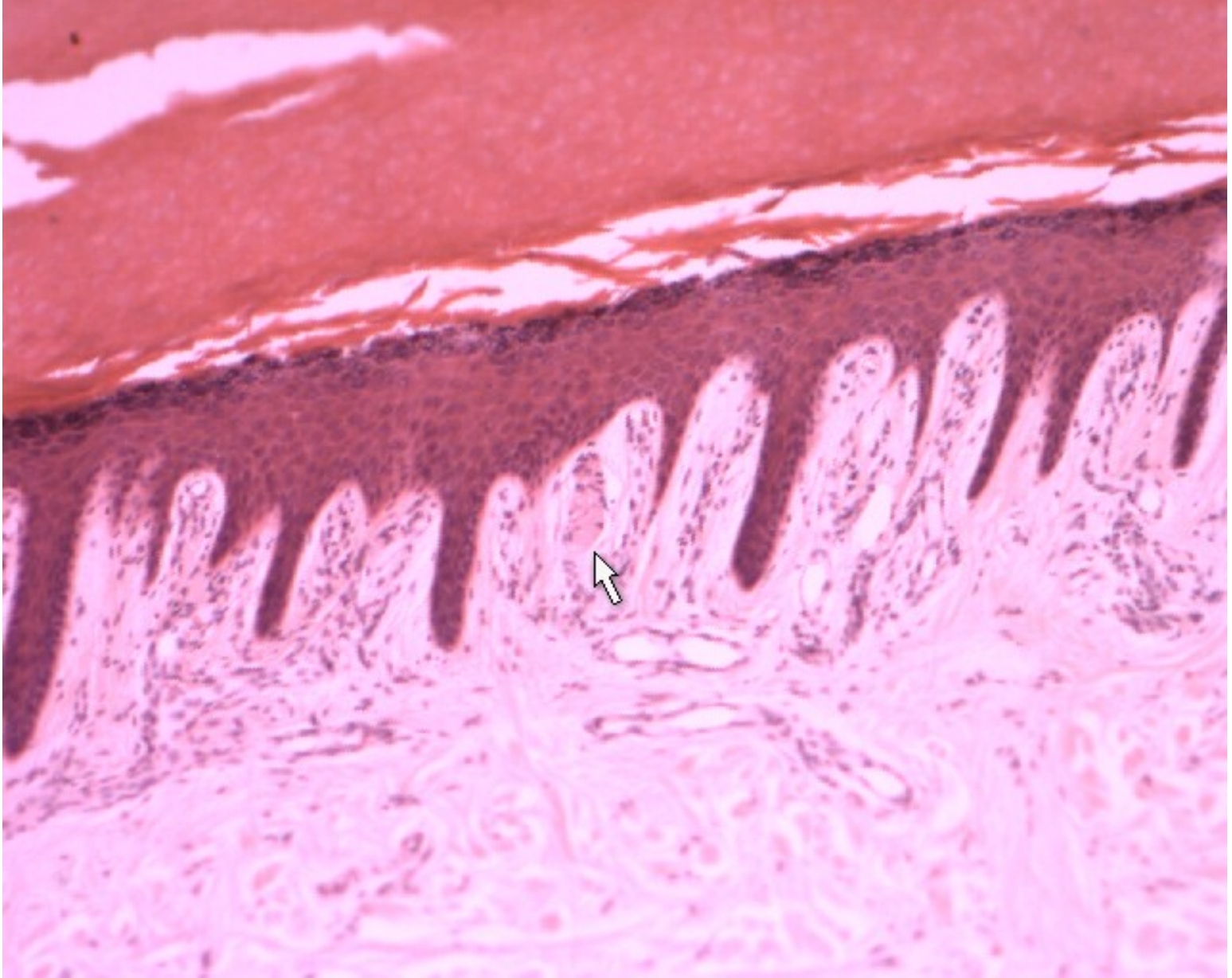
myelinated nerve fiber and Schwann cell



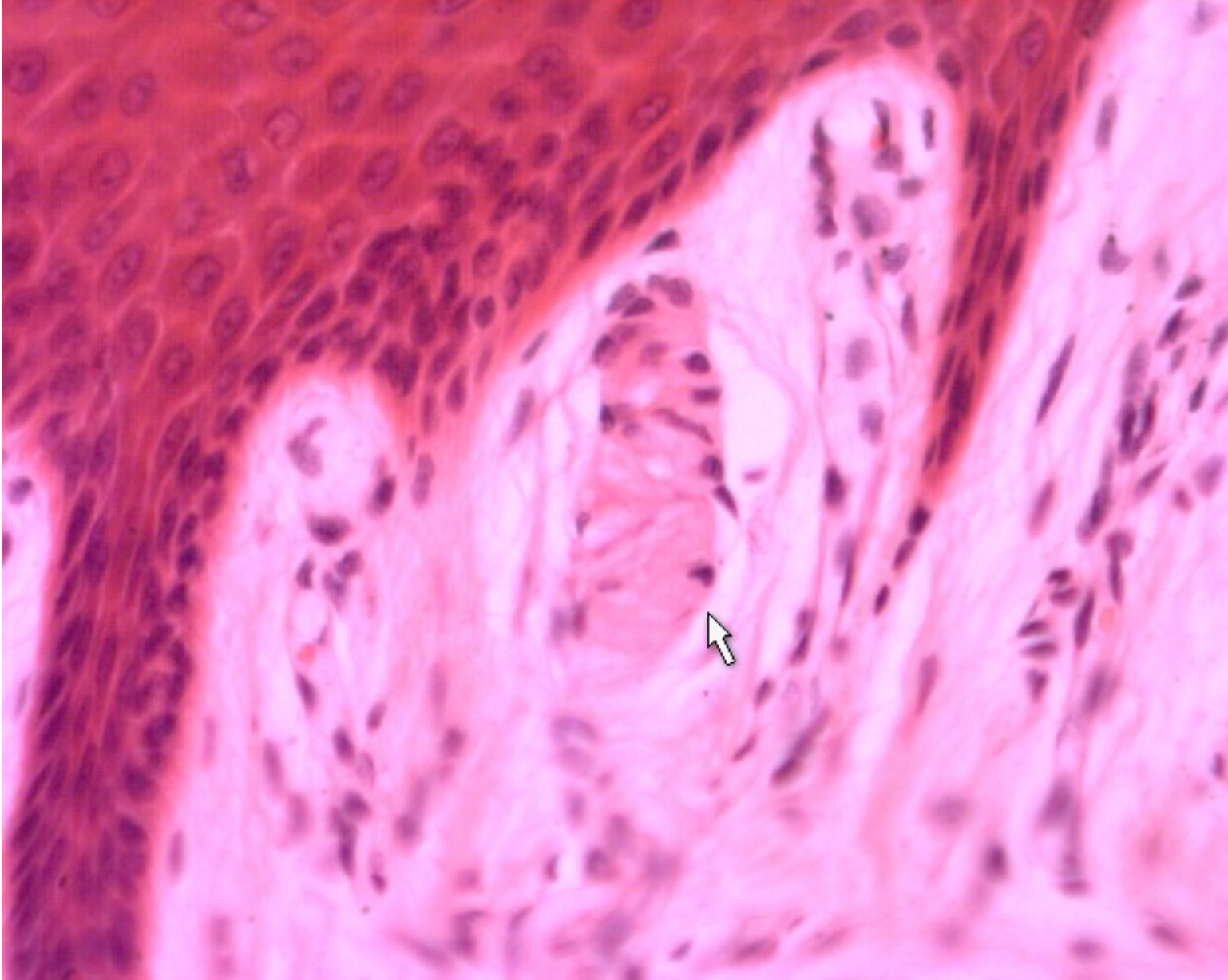
myelinated nerve fiber



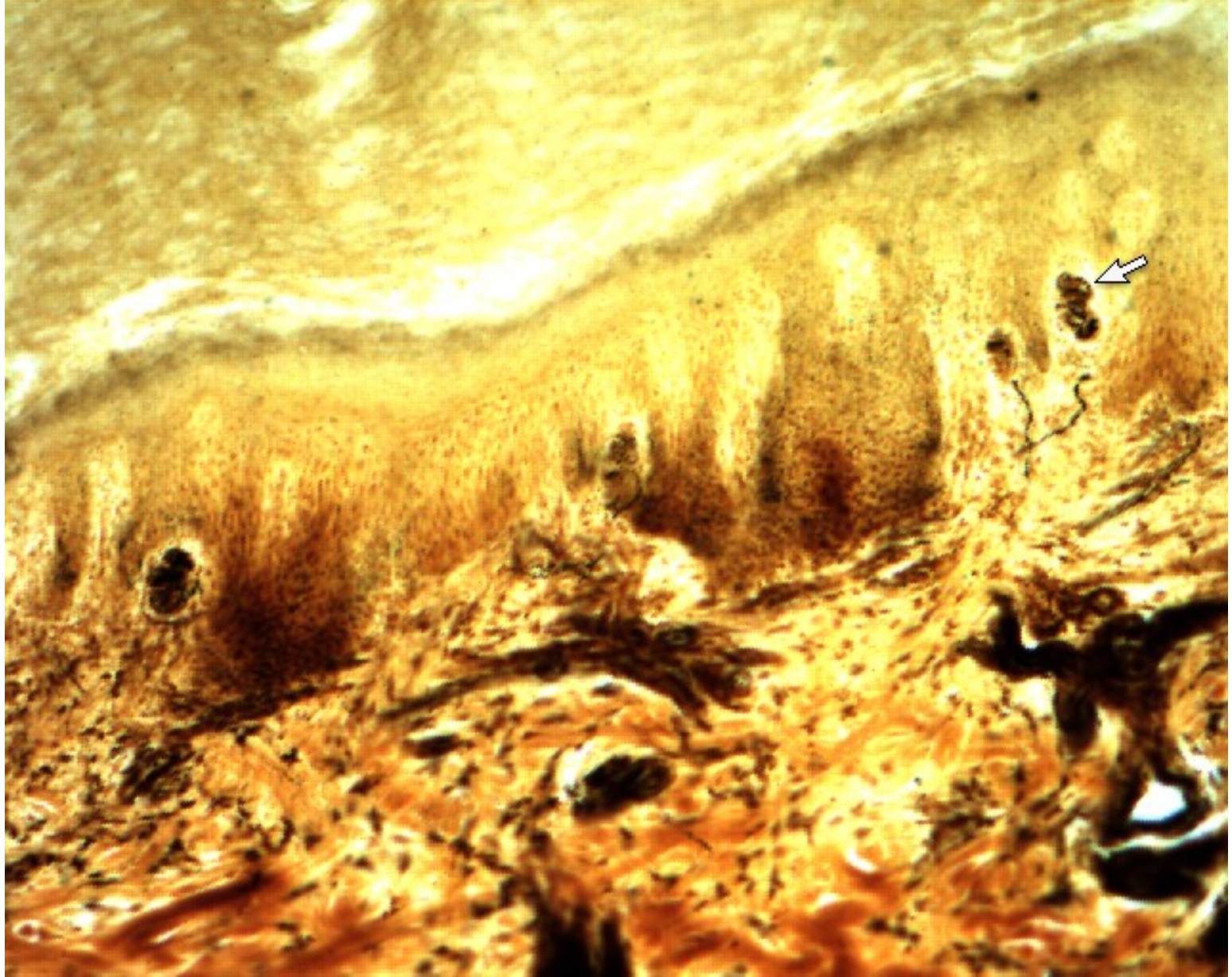
Ranvier node



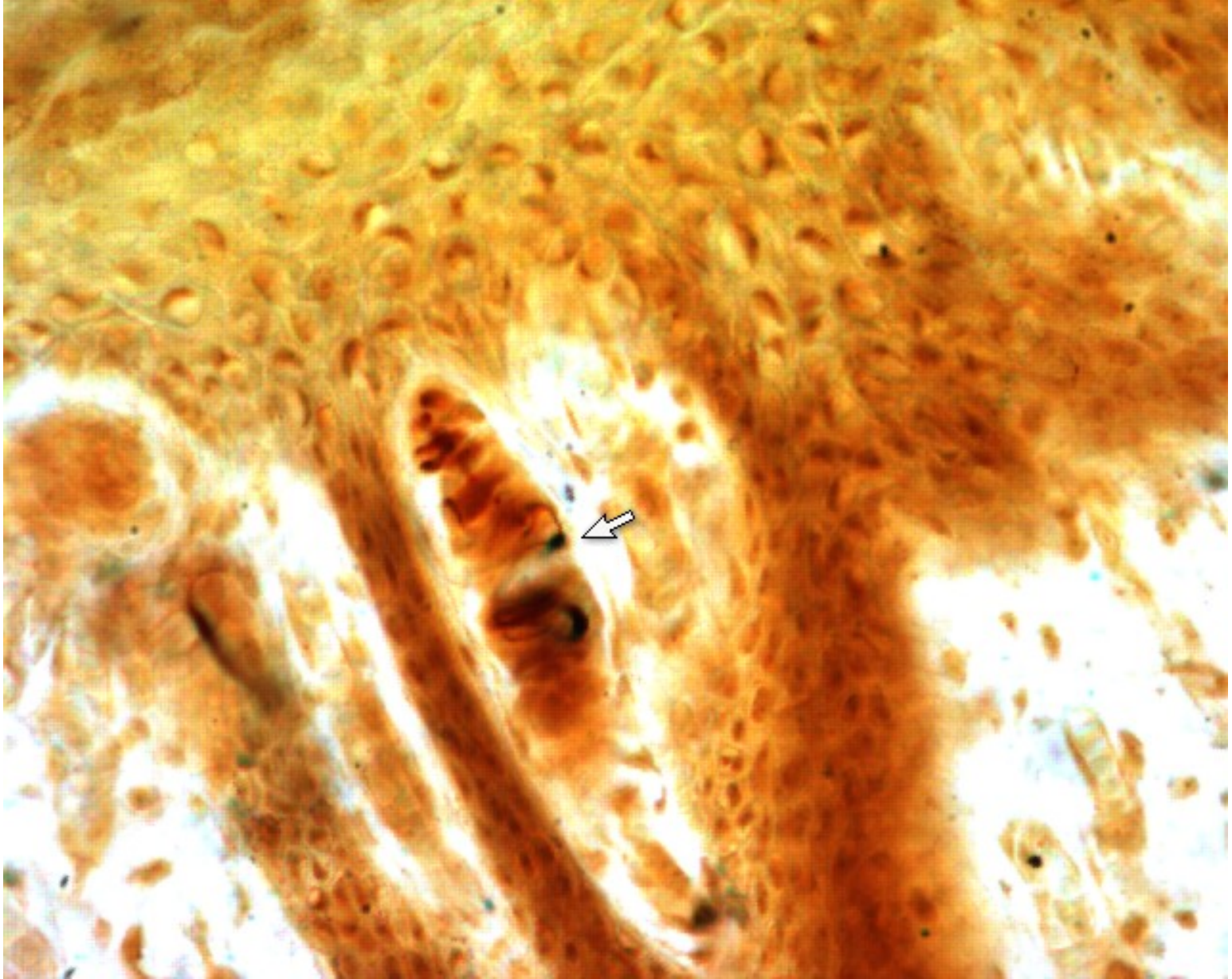
tactile corpuscle



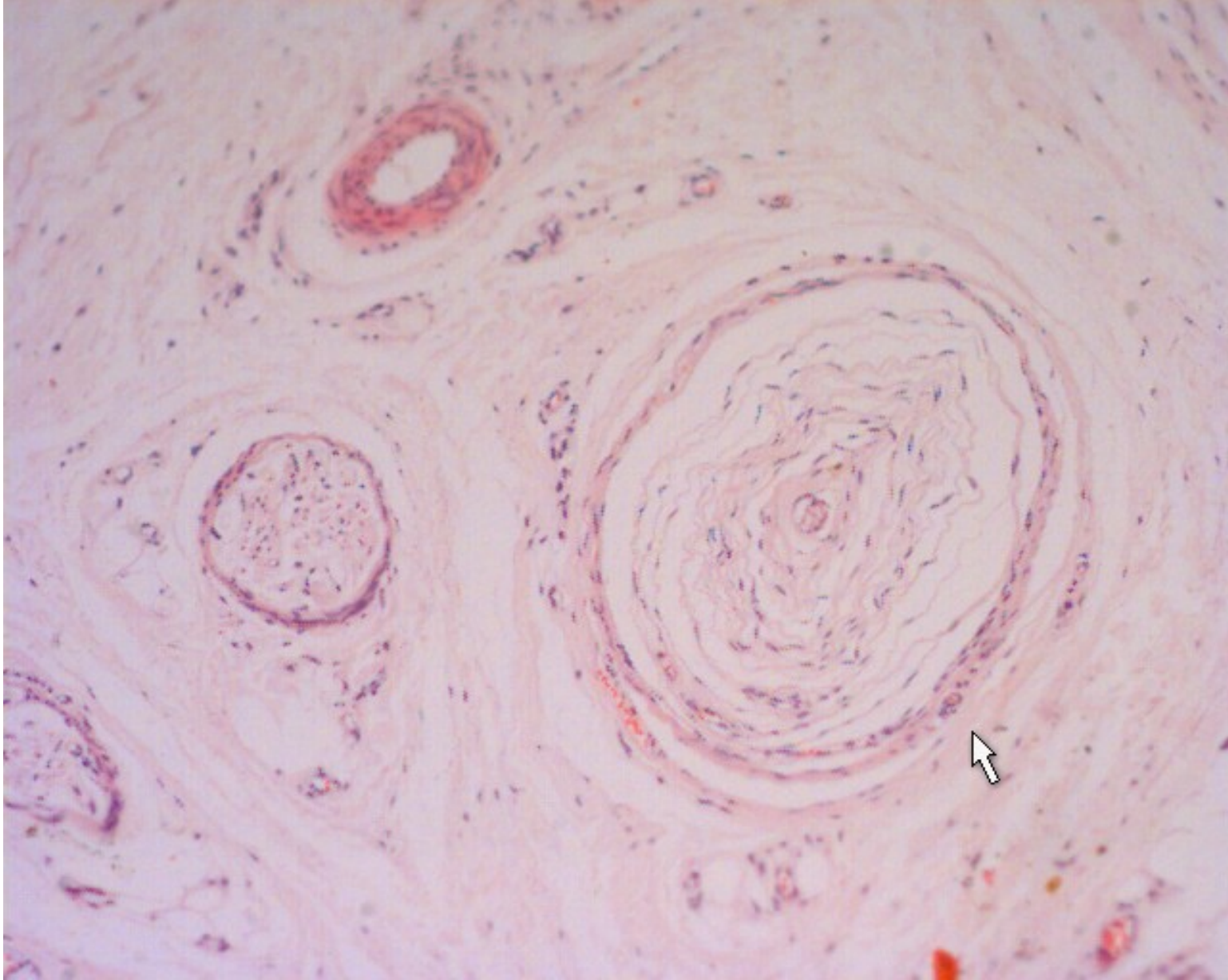
tactile corpuscle



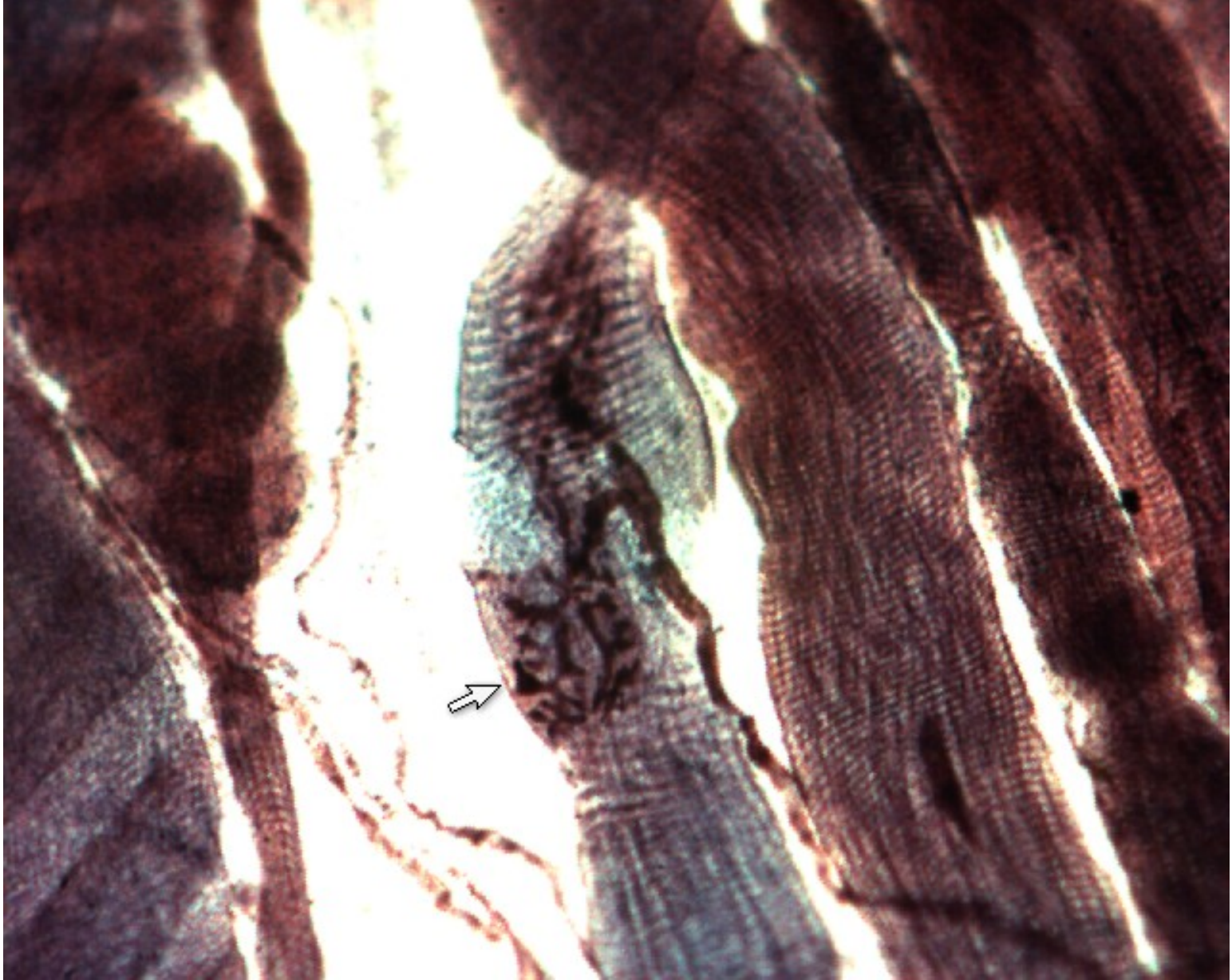
tactile corpuscle



Tactile corpuscle



lamellar corpuscle



motor end plate